

National Athletic Trainers' Association Position Statement: Preventing and Managing Sport-Related Dental and Oral Injuries

Trenton E. Gould, PhD, ATC*; Scott G. Piland, PhD, ATC*; Shane V. Caswell, PhD, ATC†; Dennis Ranalli, DDS, MDS‡; Stephen Mills, DDS§; Michael S. Ferrara, PhD, ATC, FNATA||; Ron Courson, ATC, PT, NREMT-I, CSCS¶

*School of Kinesiology, The University of Southern Mississippi, Hattiesburg; †Athletic Training Program, George Mason University, Manassas, VA; ‡School of Dental Medicine, University of Pittsburgh, PA; §Just for Kids Pediatric Dentistry, Scarborough, ME; ||College of Health and Human Services, University of New Hampshire, Durham; ¶Department of Sports Medicine, University of Georgia, Athens

Objective: To provide athletic trainers, health care professionals, and all those responsible for the care of athletes with clinical recommendations for preventing and managing sport-related dental and oral injuries.

Background: Participation in competitive sports continues to grow at both the interscholastic and intercollegiate levels. Therefore, exposure to, and the incidence of athletic-related injury, including orofacial injury, will also likely increase. At the time of this writing, the leading governing agencies for interscholastic (National Federation of State High School Associations) and intercollegiate (National Collegiate Athletic Association) sports require only protective orofacial equipment (eg, mouthguards) for 5 and 4, respectively, of their sanctioned sports. Although orofacial injuries represent a small percentage of all sport-related injuries, the financial burden associated with

these injuries (eg, tooth avulsion) can exceed \$15 000 over an adult life. Therefore, effective management of sport-related dental injuries is critical to the long-term financial, physical, and emotional health of people who have experienced dental trauma.

Recommendations: Based upon the current evidence regarding sport-related orofacial injury, we provide recommendations related to planning considerations, education, and mouthguard efficacy, material, fabrication, and care considerations. Additionally, suggested best practices for managing sport-related dental injury are also given for athletic trainers and other health care professionals.

Key Words: mouthguard, tooth avulsion, tooth fracture, sports dentistry

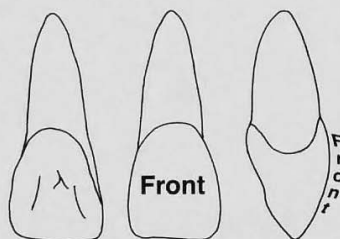


Although participation in sports and recreational activities is an important component of an overall healthy lifestyle, many of these activities are associated with a risk of injury. Specifically, several groups^{1–3} investigating injury rates across non-mouthguard-mandated sports (eg, baseball, basketball, soccer) estimated that orofacial injury rates ranged from approximately 3% to 38% of all sport-specific injuries. As participation numbers in competitive sports continue to grow at the interscholastic (approximately 7.2 million)⁴ and intercollegiate (approximately 500 000)⁵ levels, injury exposures will certainly increase, as will the likely occurrence of injury.

To address traumatic dental injuries, a variety of dental injury-management protocols are available. One tool familiar to athletic trainers (ATs) is the Emergency Treatment Card (Figure 1)⁶ from the Academy for Sports Dentistry. Whereas the card serves as an excellent resource, it does not cover the broader range of dental injuries likely to be encountered by practicing ATs. Another example, likely less familiar to the AT, is the “Guidelines for the Evaluation and Management of Traumatic Dental Injuries”⁷ document, which was published by the International Association of Dental Traumatology (IADT) and based on a series of 2012 papers^{8–10} published in the *Journal of Dental Traumatology*. To further assist clinicians, the IADT



Emergency Treatment of Athletic Dental Injuries



Professionally-made, properly fitted Custom Mouthguards are recommended for all contact and collision sports.
See www.academyforsportsdentistry.org

AVULSION (Entire Tooth Knocked Out)

Replantation within 5-10 minutes is critical for replantation. Minutes matter. If the root of the tooth has debris on it, rinse the root with water. If the root appears clean, grasp the crown between your thumb and first finger with the smooth flat surface forward.
(see diagram above)

If it is an upper tooth place the other hand on top of the person's head to stabilize it then push firmly and hold the tooth in place. When the tooth is seated into its original position, it must be held there by hand or with a wad of wet paper tissue to keep it in place. Do not worry about getting the tooth in 'correctly' it can be adjusted by the dentist later during splinting. Bleeding can be controlled by uninterrupted direct pressure for 5 minutes.

If no one is prepared to replant the tooth, if the injured patient is unwilling or unable to cooperate with immediate replantation, or if the damage to the socket and adjacent teeth is substantial; control bleeding with pressure, place the tooth in liquid such as milk or other storage media to keep it from drying.

TRANSPORT THE PATIENT AND TOOTH TO A DENTIST IMMEDIATELY.

LUXATION (Tooth in socket, but wrong position)

THREE POSITIONS

EXTRUDED TOOTH - Upper tooth hangs down and/or lower tooth has been pushed up.

1. Reposition tooth in socket using firm finger pressure like replantation.
2. Stabilize tooth by gently biting on towel or wet paper tissue.
3. **TRANSPORT IMMEDIATELY TO DENTIST.**

LATERAL DISPLACEMENT - Tooth pushed back or pulled forward.

1. No treatment at accident scene as tooth is locked in bone.
2. **TRANSPORT IMMEDIATELY TO DENTIST.**

INTRUDED TOOTH - Tooth pushed into gum-looks short

1. No treatment at accident scene as tooth is locked in bone.
2. **TRANSPORT IMMEDIATELY TO DENTIST.**

FRACTURE (Broken tooth)

1. If tooth is in pieces, save the broken portion and bring to the dental office in water or milk.
2. The nerve of the tooth may be exposed causing pain from cold, heat and air passage. Analgesics are recommended.
3. **THE PATIENT MAY COMPLETE THE GAME OR ACTIVITY BUT WILL REQUIRE DENTAL TREATMENT WITHIN 24 HOURS TO SAVE OR TREAT THE DENTAL PULP. SOONER IS BETTER.**



Academy for Sports Dentistry
118 Faye Street
P.O. Box 364
Farmersville, IL 62533
1-800-273-1788
1-217-227-3431
www.academyforsportsdentistry.org

The Academy for Sports Dentistry gratefully acknowledges the support of Dr. Samuel D. Harris for partially funding this public service project. The Academy would also like to acknowledge Dr. Alex M. Della Bella of Cincinnati, Ohio for the development of this Emergency Treatment Card. The Academy for Sports Dentistry, a professional organization dedicated to the dental needs of athletes at risk to sports injuries, recommends that every sports medicine team includes a dentist knowledgeable in sports dentistry.

**PROPERLY FITTED
MOUTHGUARDS SHOULD BE
STANDARD EQUIPMENT**

Figure 1. Academy for Sports Dentistry treatment card. Reprinted with permission.

has created a Web site (www.dentaltraumaguide.org)¹¹ based on these guidelines that serves as an online source for visual diagnosis of and treatment recommendations for a broad range of traumatic dental injuries. The guidelines are comprehensive and directed at dental professionals working in clinical settings. As such, a considerable number of the IADT guidelines are out of the scope of the athletic training profession. Therefore, a primary purpose of this position statement is to use the IADT guidelines as a foundation for clinical recommendations regarding patients with dental trauma that ATs can use for acute management and return-to-play decision making.

Although acute dental trauma still occurs, intraoral protective appliances such as mouthguards can be effective¹² in reducing the incidence of dental injury in sport. The National Federation of State High School Associations (NFHS) requires the use of properly fitted mouthguards in only 5 sports¹³ (field hockey, football, ice hockey, lacrosse, and wrestling [the last if the athlete wears braces or an orthodontic device]) and the National Collegiate Athletic Association (NCAA) mandates them in only 4 sports¹⁴ (field hockey, football, ice hockey, and lacrosse). Ostensibly, the number of NFHS-sanctioned and NCAA-sanctioned sports that require mouthguards is small compared

with the number of sports without mouthguard requirements.^{13,14} Although not all sports require mouthguard use, a meta-analysis¹² indicated that participants not wearing mouthguards (as is typical in non-mouthguard-mandated sports) were 1.6 to 1.9 times more likely to sustain an orofacial injury than participants who wore mouthguards. Because the financial burden of certain dental injuries (eg, tooth avulsions) can exceed \$15 000 over an individual's lifetime,^{15,16} effective management of these acute dental injuries is critical to the long-term oral health outcomes of patients. Therefore, a secondary goal of this position statement is to equip ATs with a set of mouthguard material, fabrication, and care recommendations to help lessen the physical, emotional, and financial costs associated with dental trauma.

The recommendations are presented using an evidence-based review that is based on the Strength of Recommendation Taxonomy (SORT) criterion scale proposed by the American Academy of Family Physicians (Table 1).¹⁷ Each recommendation is awarded a grade of A, B, or C based upon patient-oriented or disease-oriented outcomes. The SORT emphasizes outcomes-based treatments (ie, randomized controlled clinical trials). With respect to mouthguard recommendations, good-quality outcomes-based research is

Table 1. Strength of Recommendation Taxonomy (SORT)^a

Strength of Recommendation	Definition
Category A	Recommendation based on consistent and good-quality patient-oriented evidence. ^b
Category B	Recommendation based on inconsistent or limited-quality patient-oriented evidence. ^b
Category C	Recommendation based on consensus, usual practice, opinion, disease-oriented evidence, ^c or case series for studies of diagnosis, treatment, prevention, or screening.

^a Reprinted with permission from Ebell MH, Siwek J, Weiss BD, et al. Strength of Recommendation Taxonomy (SORT): a patient-centered approach to grading evidence in the medical literature, February 1, 2004, Vol 69, No 3, *American Family Physician*. Copyright ©2004 American Academy of Family Physicians. All Rights Reserved.¹⁷

^b Patient-oriented evidence measures outcomes that matter to patients: morbidity, mortality, symptom improvement, cost reduction, and quality of life.

^c Disease-oriented evidence measures intermediate, physiologic, or surrogate end points that may or may not reflect improvements in patient outcomes (eg, blood pressure, blood chemistry, physiologic function, pathologic findings).

limited by the ethical constraints of implementing an experimental design that would preclude an at-risk group from using a mouthguard, especially when mandated in a particular sport. The reader should recognize and consider these limitations when assessing specific recommendations related to planning considerations, education, clinical management of acute dental trauma, mouthguard efficacy, and mouthguard material and fabrication considerations.

RECOMMENDATIONS

Planning Considerations

1. All ATs and other health care professionals responsible for the care of athletes should be familiar with the National Athletic Trainers' Association (NATA) position statement "Emergency planning in athletics."¹⁸ When appropriate, the following recommendations and suggested best practices for clinical management should be integrated into established written emergency action plans. *Strength of recommendation: C*
2. Clinicians responsible for the dental care of athletes should identify an appropriate oral health care specialist (preferably with additional training in sports dentistry) for direct referral. The specialist can assist the AT in establishing an appropriate referral team¹⁹ (eg, endodontist, orthodontist, and oral and maxillofacial surgeon), as well as an appropriate emergency dental facility. *Strength of recommendation: C*
3. Athletic trainers and other health care professionals providing onsite care to athletes should carry a dental trauma pack with their sideline sports medicine kit. A recommended list of items for this kit is given in Table 2. These contents may be modified to meet the needs of the specific sport or team.¹⁹ *Strength of recommendation: C*

Education

4. Clinicians responsible for emergency dental care of athletes should have adequate knowledge of the structure and function of the tooth-jaw complex.^{19,20} *Strength of recommendation: C*
5. Athletic trainers and other health care professionals responsible for the emergency dental care of athletes should be able to recognize the signs, symptoms, and classifications of acute dental injury.¹⁹ *Strength of recommendation: C*

Table 2. Suggested Generic List^a of Recommended Dental-Specific First-Aid Items

General Items ^b
Academy for Sports Dentistry trauma card (quick reference)
Adhesive tape
Biohazard bags
Cotton rolls
Cotton-tip applicators
Dental floss
Elastic bandage (2 in × 48 in [5.08 cm × 121.92 cm])
Extra mouthguards
Gauze (2 in × 2 in [5.08 cm × 5.08 cm])
Gloves (examination grade, disposable)
Hand cleanser
Masks
Mouth mirror
Pocket flashlight
Scissors
Tongue depressors
Tooth culture medium
Dentist-Specific Items ^c
Arch wire
Ball burnisher
Butane cartridges
Butane torch
Dental rope or orthodontic relief wax
Eugenol
Explorer instrument (dental pick)
Hemostat
Mixing pad
Needle holder
Needles (long, short)
Plugger instrument
Pulp dressing (calcium hydroxide paste)
Spatula instrument
Spoon excavator instrument
Sutures
Syringe (aspirating)
Topical and local anesthetic
Wire cutters

^a Adapted with permission from Ranalli DN, Demas PN. Orofacial injuries from sport: preventive measures for sports medicine. *Sports Med*. 2002;32(7):409–418. Copyright 2002 by Adis International Limited. All Rights Reserved.¹⁹

^b General list of dental emergency kit items that are universal and recommended for athletic trainers working within their respective state practice acts.

^c List of specific items for team dentists to use within their scope of dental practice.

Table 3. Several Mouthguard Classification Systems

American Society for Testing and Materials ^a	American National Standards Institute/American Dental Association ^b	Standards Australia International/Australian Dental Association ^c
Type I: Thermoplastic	Type III: Custom	Custom made
Class 1: Vacuum formed	Class 1: Vacuum formed	Single-layer vacuum formed
Class 2: Mouth formed	Class 2: Model formed	Single-layer pressure formed
Type II: Thermosetting	Type II: Mouth formed	Laminated, air pressure
Class 1: Mouth formed	Class 1: Thermoplastic	Bimaxillary
Type III: Stock	Class 2: Chemical setting	Mouth formed
	Type I: Stock	Stock

^a Reprinted, with permission, from F697-00 (2006) Standard Practice for Care and Use of Athletic Mouth Protectors, copyright ASTM International, 100 Barr Harbor Drive, West Conshohocken, PA 19428.²⁴

^b Reprinted from ANSI/ADA Standard No. 99-2001, *Athletic Mouth Protectors and Materials*. ©American Dental Association.²⁵

^c Adapted from "The fabrication, use and maintenance of sports mouthguards," by Standards Australia International/Australian Dental Association, p. 4. Copyright 2013 by the Australian Dental Association. http://www.ada.org.au/app_cmllib/media/lib/1304/m574050_v1_mouthguard%20handbook%20.pdf.²⁶

6. Given the overlap between sport-related dental and concussion injury mechanisms, ATs and other health care professionals should perform a thorough concussion evaluation (see NATA position statement on the management of sport concussion²¹) in conjunction with the orofacial examination. *Strength of recommendation: C*
7. Health care professionals, athletes, parents, and coaches should be educated on the importance of wearing a properly fitted mouthguard.^{12,19,20,22,23} *Strength of recommendation: C*
8. Clinicians, athletes, parents, and coaches should be educated on the classification systems used to characterize mouthguards (Table 3).^{20,22–26} *Strength of recommendation: C*
9. Athletic trainers and other health care professionals, athletes, parents, and coaches should know the international, national, and state governing body rules, regulations, and requirements related to mouthguard use associated with various sports.^{14,19,27,28} *Strength of recommendation: C*

Dental and Oral Injury Classification and Acute Care

Tooth Fractures.

10. **Crown Infractures.** Crown infractures do not represent a dental emergency. Although referral is indicated for treatment, it may be postponed temporarily, thereby allowing the athlete to immediately return to play with a mouthguard in situ to reduce the risk of further injury.^{29–31} *Strength of recommendation: C*
11. **Enamel-Only Crown Fractures.** An athlete who complains of roughness along the incisal edge of a tooth crown subsequent to a traumatic force likely has an enamel-only fracture. This injury is not a dental emergency and the athlete may return to play immediately with a mouthguard in situ to reduce the risk of further injury.^{29,31,32} *Strength of recommendation: C*
12. **Enamel-Dentin Crown Fractures.** The involved tooth may exhibit discomfort, but the athlete can return to play as pain permits with a mouthguard in situ to reduce the risk of further injury. The athlete should be referred to a dentist and managed definitively within 24 hours.^{29–31} *Strength of recommendation: C*

If the tooth fragment can be located at the scene, it should be placed in a liquid such as water, saline, or milk and sent with the athlete to the dentist.³¹ *Strength of recommendation: C*

13. **Enamel-Dentin-Pulp Fractures.** The involved tooth may exhibit sensitivity to thermal changes, air exposure, or touch due to mastication resulting in pain. The athlete can return to play as pain allows with a mouthguard in situ to reduce the risk of further injury but should be referred to a dentist and treated within 24 hours.²⁹ *Strength of recommendation: C*

If the pulp is vital, a focal hemorrhage will be evident within the yellow dentin layer, and the athlete will likely report acute pain. The patient should be referred immediately to a trauma-ready dentist for definitive treatment.³¹ *Strength of recommendation: C*

If the tooth fragment can be located at the scene, it should be placed in a liquid such as water, saline, or milk and sent with the athlete to the dentist.³¹ *Strength of recommendation: C*

Root Fractures. Only radiographic examination can verify the root fracture location and eliminate luxation from the differential diagnosis.

14. **Apical One-Third Root Fractures.** Apical one-third root fractures frequently go undetected, as little or no rotational mobility is observed on palpation and pain is not often reported. These injuries do not represent a dental emergency and, although referral is indicated for treatment, it may be postponed temporarily, thereby allowing the athlete to immediately return to play with a mouthguard in situ to reduce the risk of further injury.^{29,31} *Strength of recommendation: C*
15. **Middle One-Third Root Fractures.** Middle one-third root fractures may be displaced, making the injured tooth appear elongated compared with the adjacent teeth. Athletic trainers and other health care providers providing onsite care may reposition a displaced fractured coronal segment with finger pressure while wearing examination gloves. Alternatively, the athlete can be asked to gently bite down on a sterile gauze pad to prevent further displacement.³¹ *Strength of recommendation: C*

The involved tooth may exhibit discomfort, but the athlete can return to play as pain permits with a

mouthguard in situ to reduce the risk of further injury. However, if the visible tooth is markedly loose, the athlete should discontinue playing to avoid further injury. The athlete should be referred to a trauma-ready dentist or emergency facility for management within 24 hours.²⁹ *Strength of recommendation: C*

16. **Cervical One-Third Root Fractures.** Cervical one-third root fractures often present as a crown segment dangling from lacerated, bloody gingival tissue. The athlete should be asked to gently bite down on a sterile gauze pad to prevent further displacement.³¹ *Strength of recommendation: C*

The involved tooth may exhibit discomfort, but the athlete can return to play as pain is tolerated with a mouthguard in situ to reduce the risk of further injury. However, if the tooth is significantly loose, the athlete should discontinue playing to avoid further injury. He or she should be referred to a trauma-ready dentist or emergency facility for management within 24 hours.²⁹ *Strength of recommendation: C*

Tooth Displacement Injuries.

17. **Tooth Concussions and Subluxations.** Concussions and subluxations do not represent dental emergencies, thereby allowing the athlete to immediately return to play. Although referral is indicated for treatment, it may be delayed up to 24 hours. The tooth should be observed periodically by the dentist for any clinical or radiographic changes.^{33,34} *Strength of recommendation: C*
18. **Lateral and Extrusive Luxations.** Lateral and extrusively luxated teeth must first be repositioned within the alveolar socket using finger pressure and proper barrier protection. The athlete should then be asked to bite down on a sterile gauze pad to temporarily splint the tooth in preparation for transport. Immediate removal from participation and referral to a trauma-ready dentist or emergency facility is indicated.³⁵ *Strength of recommendation: C*
19. **Intrusive Luxations.** Athletes with intrusively luxated teeth should be immediately removed from participation and transported to a trauma-ready dentist or emergency facility, as treatment options depend on whether the root apex is immature or fully formed (this requires radiographic validation).^{35–38} *Strength of recommendation: C*
20. **Avulsions (Exarticulations).** The athlete should be immediately removed from participation. Prompt intervention by the AT or other health care provider is essential to enhance the probability of a successful clinical outcome. The avulsed tooth must first be located and, if the athlete is alert and oriented, replacement (replantation) attempted. Speed of replantation is the single most important factor for optimal healing and should occur within 5 minutes. The AT may attempt replantation by inserting the root end into the cavity and ensuring proper orientation of the tooth by comparison with the position of the adjacent teeth.^{39–45} *Strength of recommendation: B*

To prevent additional trauma to the periodontal ligament (PDL), the clinician should refrain from handling the tooth by its root, brushing or scrubbing debris from the tooth, or sterilizing the tooth with boiling water or chemicals.^{46,47} *Strength of recommendation: C*

If visible debris is on the tooth surface, the AT or other health care professional can gently rinse (for a

maximum of 10 seconds) the surface under a gentle flow of a cold water, milk, or physiologic saline.^{46,47} *Strength of recommendation: C*

Once the tooth has been replanted, the athlete should bite down on a sterile gauze pad to stabilize it before being immediately transported to a trauma-ready dentist for definitive treatment.⁴⁶ *Strength of recommendation: C*

If the avulsed tooth cannot be replanted immediately and completely, the tooth should be submerged in a storage medium to prevent the PDL cells from drying. Hanks' Balanced Salt Solution is the optimal storage medium for avulsed teeth. However, cold low-fat milk is an acceptable alternative. An avulsed tooth should not be wrapped in dry gauze or a dry paper towel.^{48–54} *Strength of recommendation: B*

Mouthguard Effectiveness

21. Mouthguards are consistently effective at protecting against orofacial injuries.^{12,55–68} Athletic trainers, coaches, and parents should encourage athletes to wear properly fitted mouthguards during sports activities with an increased risk of orofacial injury.¹² *Strength of recommendation: A*
22. Mouthguards are not recommended for preventing mild traumatic brain injury or sport-related concussion, as no quality scientific evidence currently supports using any type of mouthguard or mouthguard material for this purpose.^{12,69–71} *Strength of recommendation: A*
23. Properly fitted mouthguards can be used by athletes in both aerobic and anaerobic sports. Use of these devices has no negative effect upon ventilatory or strength measures.^{40,72–78} *Strength of recommendation: B*
24. Mouthguards, including mandibular orthopaedic repositioning appliances (MORAs), should not be recommended to athletes to improve performance (eg, strength or balance). No quality evidence is currently available to support the use of any such material or device for ergogenic effects.^{41–45,79–82} *Strength of recommendation: B*

Mouthguard Material, Fabrication, and Care Considerations

25. Athletic trainers and other health care professionals should be familiar with current mouthguard designs and materials and understand that many variables can influence the effectiveness of a mouthguard. These variables may include the type and thickness of material used, area of coverage, state of protected anatomy, and direction, force, and nature of impact.^{12,83–87} *Strength of recommendation: C*
26. Although mouthguards do not currently have to meet any safety standards, ATs and other health care professionals responsible for fabricating mouthguards should understand the general principles for doing so, including their physical and mechanical properties (Table 4).^{25,26} *Strength of recommendation: C*
27. While working within the scope of their respective state practice acts, clinicians responsible for fabricating and fitting athletic mouthguards should strive to meet the suggested fabrication (ie, fit) recommendations in Table

Table 4. General Principles and Guidelines for Mouthguard Materials

General Material Principles ^a	General Material Guidelines ^b
•Easy to manipulate	Shore A durometer, 37°C
•Resistant to damage from hot water	Liner: 40–60
•Sufficient elastic modulus to reduce stress beneath material at point of impact	Shell: 55–95
•Sufficient rigidity to distribute forces over a larger surface area of the dentition	Water absorption, 37°C
•Sufficient toughness to resist cutting by biting	<0.5 weight (%)
•Resistant to fracture under sudden impact	Impact test, 23°C
•Resistant to water absorption in order to prevent tainting by mouth fluids	≥65% absorbed
•Ability to withstand normal cleaning compounds	Tear strength, 37°C
•Resistant to low pH	≥200 N·cm ⁻¹
•Tasteless and odorless	

^a Adapted from “The fabrication, use and maintenance of sports mouthguards,” by Standards Australia International/Australian Dental Association, p. 4. Copyright 2013 by the Australian Dental Association. http://www.ada.org.au/app_cmslib/media/lib/1304/m574050_v1_mouthguard%20handbook%20.pdf.²⁶

^b Reprinted from ANSI/ADA Standard No. 99-2001. *Athletic Mouth Protectors and Materials*. ©American Dental Association.²⁵

5. In younger athletes with primary or mixed dentition, the mouthguard should be routinely inspected for fit and retention to accommodate tooth eruption, occlusal development, and growth.²⁶ *Strength of recommendation: C*
28. Athletes should be instructed to cleanse the mouthguard with a mild antimicrobial agent and rinse it thoroughly in tepid water both before and after use.^{24,26} *Strength of recommendation: C*
29. Athletes should be instructed to store the mouthguard in a clean, rigid, ventilated plastic container.^{24,26} *Strength of recommendation: C*
30. Most custom and commercially available mouthguard materials are thermoplastic resins. Therefore, mouthguards should not be exposed to prolonged direct sunlight or sources of heat, as deformation may occur and reduce the protective capabilities of the mouthguard.^{24,26} *Strength of recommendation: C*
31. The athlete should examine the mouthguard daily for fit and for any damage (eg, tear in material or loss of resiliency). The mouthguard should be replaced if it is loose or damaged.^{24,26} *Strength of recommendation: C*

players, hard surfaces, or sport equipment. Protective equipment, such as a properly fitted mouthguard, both absorbs and distributes the traumatic forces of impact, thereby reducing (but not eliminating) the incidence of dental injuries.^{12,22,89,90} However, when injuries to the tooth-jaw complex do occur, they often require immediate intervention by the AT, as well as referral to the appropriate oral health care specialist. With respect to the adult permanent dentition, as for every situation, the AT's acute treatment goal is to deliver the best possible health care to the athlete.¹⁹

A dental injury prognosis depends on several factors which, at minimum, include the general physical and oral health of the athlete. As elapsed time from injury to definitive treatment by the appropriate oral health care specialist increases, the general prognosis worsens.¹⁹ Because time is such an important component in the prognosis, ATs should have clear dental-injury management guidelines incorporated into their written emergency action plans. The development and implementation of a dental response plan should follow the guidelines set forward by the NATA position statement on emergency planning in athletics.¹⁸ At the least, the plan should identify appropriate oral health care specialists for direct referral. For example, ATs working with youth leagues, junior high, or high school sports should refer an athlete with a dental injury to the youth's pediatric or general dentist. Collegiate ATs are encouraged to identify a team dentist to serve as a part of either the onsite or on-call sports medicine team. Preferably, a team dentist will have additional training in sports dentistry, such as that provided by the Academy for

BACKGROUND AND LITERATURE REVIEW

Planning Considerations

Common injuries to the permanent dentition often occur as the result of falls, motor vehicle accidents, violence, and sports. Similarly, sport-related traumatic dental injuries most often result from falls, collisions, or contact with other

Table 5. Suggested Specifications for Fabricating Mouthguards for Athletes in High-Contact and Low-Contact Sports^a

Clinical Fabrication Considerations ^b	
High-Contact Sports	Low-Contact Sports
Full enclosure of maxillary teeth to distal surface of second molar for sports with high occlusal loads	Full enclosure of maxillary teeth to distal surface of first molar for sports with low occlusal loads
≈ 2- to 3-mm Thick on labial aspect	≈ 3-mm Thick on occlusal aspect
≈ 2 mm On palatal aspect	Edge of labial flange rounded
Edge of palatal flange tapered	Adjusted occlusion for even contact
Palatal flange should extend about 10 mm above gingival margin	Labial flange should extend to within 2 mm of vestibular reflection

^a Note: At least 1 study⁸⁸ suggested no additional shock-absorption protection is afforded by extending mouthguard onto the palate.

^b Adapted from “The fabrication, use and maintenance of sports mouthguards,” by Standards Australia International/Australian Dental Association, p. 4. Copyright 2013 by the Australian Dental Association. http://www.ada.org.au/app_cmslib/media/lib/1304/m574050_v1_mouthguard%20handbook%20.pdf.²⁶

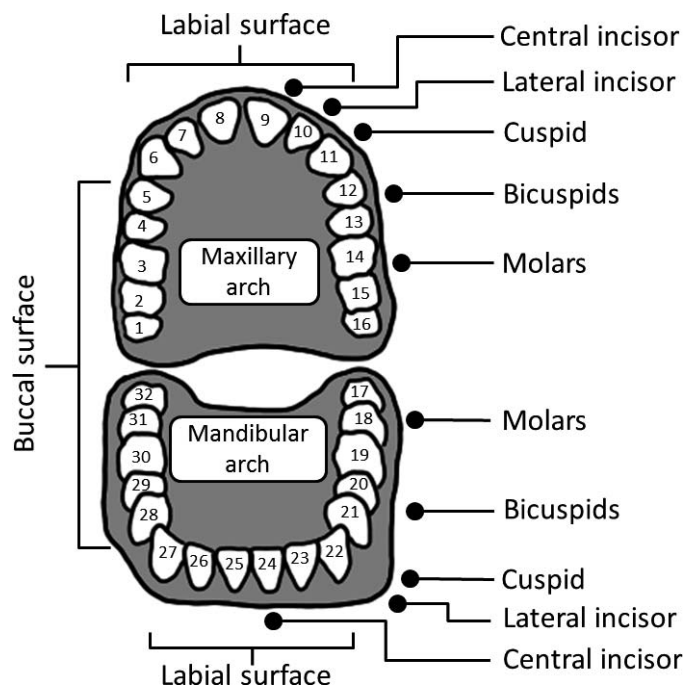


Figure 2. Tooth identification and numbering system.

Sports Dentistry. A team dentist can help the AT establish an appropriate referral team (eg, endodontist, orthodontist, and oral and maxillofacial surgeon), as well as an appropriate emergency dental care facility.¹⁹ In addition to personnel and facilities, ATs should ensure that all necessary dental emergency equipment is available and in working order.¹⁸ The AT should work collaboratively with the team dentist to assemble a dental emergency kit stocked with dental-specific first-aid items (Table 2).¹⁹ To avoid being confused with other first-aid items, the dental emergency kit should be separate, such as in a plastic utility box that affords protection from weather conditions and quick access in the event of injury.¹⁹ The dental-injury management guidelines should be rehearsed as part of the annual emergency action plan review, as personnel, equipment, and facilities may change.¹⁸

Education

Dental Anatomy and Function. The adult permanent dentition is composed of 32 teeth: 16 teeth in the maxillary arch and 16 in the mandibular arch. The normal adult has 2 central incisors, 2 lateral incisors, 2 cuspids (canines), 4 bicuspid (premolars), and 6 molars in each arch (Figure 2). The teeth are held in place by underlying alveolar bone and supported by the surrounding oral gingival tissues (Figure 3A). Each tooth contains a visible crown and 1 or more roots. The crown is made of an external hard layer of enamel and an underlying porous layer of dentin. The protective enamel layer is a white shade and is composed of prisms. Conversely, dentin is a yellow shade and is composed of tubules that communicate with the dental pulp (Figure 3A).

The primary function of the root is to anchor the tooth in place. However, unlike the enamel covering the crown, the outer layer of the root is made of cementum over a layer of dentin. The root is suspended in place within the alveolar

socket by the PDL. The PDL attaches on 1 surface to the cementum of the root and on the other to the alveolar bone within the socket (Figure 3A). Beneath the dentin of both the crown and root lies the dental pulp. The dental pulp contains cells, blood vessels, nerves, and lymphatic tissues that are housed within the coronal pulp chamber and the root canal, terminating at the apical foramen. The dental pulp has 4 basic functions: formative, nutritive, sensory, and defensive.

The formative function is mesodermal in origin; young pulp consists of undifferentiated mesenchyme cells that, when stimulated, differentiate to form odontoblasts, which produce dentin to protect the pulp.⁹¹ As the pulp ages, fewer stem cells are available, but by this time, the deposition of reparative dentin has progressed sufficiently to reduce the size of the pulp chamber and complete formation of the root apex.

The nutritive function of the dental pulp is performed by the tissue fluids that nourish the dentin via the odontoblasts.

The sensory function of the dental pulp mediates only the sensation of pain, regardless of the stimulus, via myelinated sensory nerve fibers. Unmyelinated motor nerve fibers mediate the reflex arc by acting on the muscles of the blood vessels to regulate lumen size.

The defensive function of the dental pulp produces a non-stimulus-specific reaction to any irritation. For mild to moderate irritations, the pulp stimulates the production of reparative dentin. For moderate to severe irritations, the pulp initiates the inflammatory process.⁹² For chronic or severe irritations, the pulp progresses through the phases of hyperemia, excess fluid production, infection, and necrosis.

The onsite AT must understand the anatomy and physiology of the tooth-jaw structure and function as the basis for acute dental-injury management.^{30,31,35,38,46} As with all treatment decisions, for informed consent, the patient must be made aware of the pros and cons of alternative treatment modalities.

Signs, Symptoms, Treatment, and Classifications of Dental Injuries

Tooth Fractures. Tooth fractures may be further categorized as crown infractions, enamel-only fractures, enamel-dentin fractures, and fractures that extend through the enamel and dentin into the pulp.^{30,31}

Crown Infractions. These injuries are characterized by disruption of the enamel prisms from a traumatic force.^{31,93} Upon transillumination, these injuries present as craze lines (small cracks that affect only the enamel) within the crown region of the tooth.

Enamel-Only Fractures. Enamel-only fractures are mild and often appear as roughness along the incisal edge of the tooth crown (Figure 3B).^{31,32} Some athletes may not even realize that such an injury has occurred because enamel-only fractures are usually not sensitive to touch or temperature stimuli and may only feel rough to the athlete's tongue. Similar to crown infractions, enamel-only crown fractures do not represent a dental emergency and referral may be delayed. However, referral to a dentist is indicated for further diagnostic evaluation and baseline documentation. Treatment options will likely include smoothing of the rough enamel incisal edge or placement of a restoration with an appropriate dental material.^{31,94,95}

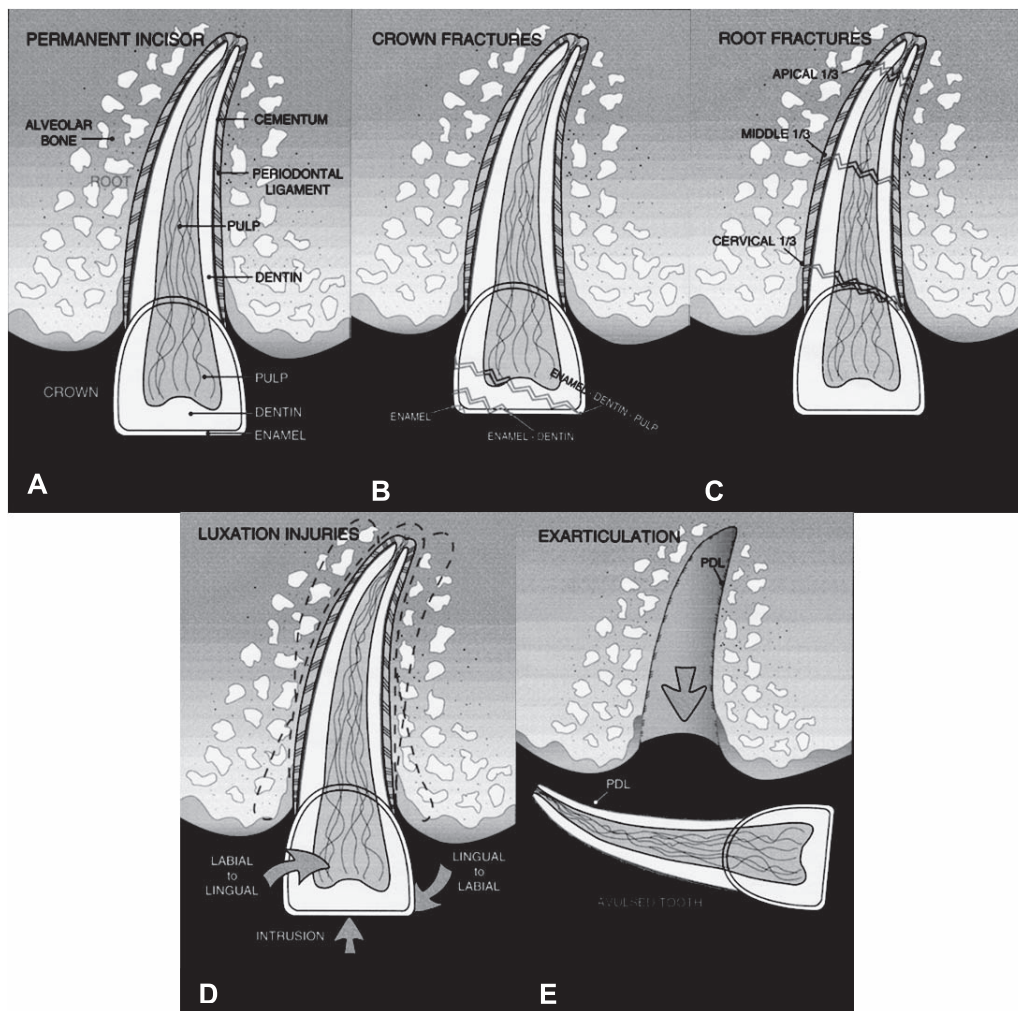


Figure 3. Normal and pathologic anatomy of typical maxillary permanent central incisor. **A**, Basic anatomical features of maxillary permanent central incisor and supporting structures. **B**, Types of crown fractures in the maxillary permanent incisor: enamel only, enamel-dentin, and enamel-dentin-pulp. **C**, Types of root fractures in maxillary permanent central incisor: apical one-third, middle one-third, cervical one-third. **D**, Types of luxation injuries in maxillary permanent central incisor: intrusive luxation, lateral luxation. **E**, Exarticulation of maxillary permanent central incisor (ie, avulsed tooth).

Enamel-Dentin Crown Fractures. Enamel-dentin crown fractures typically present as thin white tooth enamel surrounding the underlying yellow layer of more porous dentin (Figure 3B).^{31,96} In addition, the athlete often reports sensitivity to air, cold, or touch when the tooth pulp is vital.^{31,96} The athlete may return to participation as discomfort permits, and referral can be delayed up to 24 hours. The primary objective in this circumstance is to cover the exposed dentin with a biologically acceptable agent to reduce sensitivity and protect the pulp from further damage. If a dental emergency kit is available and onsite personnel have sufficient knowledge and experience, a thin layer of calcium hydroxide paste or a mixture of zinc oxide with eugenol may be placed temporarily over the exposed dentin. Treatment options include aesthetic restoration or bonding the fractured crown segment back to the injured tooth.^{97–99} Otherwise, the dentist is likely to perform an aesthetic, tooth-colored restoration using an appropriate dental material.^{27,31,94,95,100,101}

Enamel-Dentin-Pulp Fractures. Crown fractures that extend through the enamel and dentin into the pulp are more problematic (Figure 3B).^{27,31,94,95,100–105} If the pulp is

vital, a focal spot of hemorrhage will be evident within the yellow dentin layer.¹⁰⁴ In addition, the athlete may report acute pain. In contrast, if the pulp is nonvital, no hemorrhage will be present. Instead, either seepage of putrescent exudate or a dry, hollowed-out area will be evident.^{31,105} A foul odor may emanate from the tooth and the athlete may not report pain. Regardless, this tooth injury is considered subacute, and the athlete can return to play as pain allows. Referral to a trauma-ready dentist should occur within 24 hours for definitive treatment.¹⁰¹ Diagnosis and treatment depend on the following factors: the time interval between the injury and the initiation of treatment (the longer the interval, the poorer the prognosis), status of the dental pulp (vital versus nonvital), and the degree of root end closure at the apex of the tooth (as determined via a periapical radiograph). Onsite care providers will generally not be able to make a definitive assessment.

For both enamel-dentin and enamel-dentin-pulp fractures, if the tooth fragment can be located, it should be placed in a liquid such as water, saline, or milk and sent with the athlete to the dentist. The liquid is intended to prevent desiccation of the fragment and allow for the most

aesthetic reattachment, whereas with a tooth avulsion, one is attempting to keep cells alive. If the tooth fragment dries out, it may turn chalky white and not reattach aesthetically. In this case, most liquids are acceptable except for alcohol or acetone (which are drying agents) or bleach or peroxide (which alter the aesthetics). Water is optimal due to accessibility.

Root Fractures. Less common than crown fractures, root fractures may be further categorized as affecting the apical one-third, middle one-third, or cervical one-third.^{30,31,106–109}

Apical One-Third Root Fractures. These fractures are the least problematic and often heal spontaneously without intervention.^{30,31,110} The alveolar bone encasing the deepest portion of the root apex holds the tooth firmly and serves as a natural splint (Figure 3C). In addition, the distance between the root apex and the gingival sulcus restricts bacterial ingress from the mouth to the fracture site. This fracture frequently goes undetected, as little or no rotational mobility is observed on palpation and pain is not often reported. In the absence of radiographic equipment, the onsite provider may not be able to make a definitive diagnosis.

Middle One-Third Root Fractures. These fractures may be displaced with the coronal segment extruded, making the injured tooth appear elongated compared with the adjacent teeth (Figure 3C).^{30,31} Gentle rotational palpation gives information regarding the severity of the fracture, but radiographs are needed for definitive diagnosis.^{31,108,109,111–113} The underlying principles for managing displaced middle one-third root fractures are analogous to those used by orthopaedic surgeons for managing displaced long bone fractures: reduce the fracture by bringing the segments into close approximation, splint the fracture for a suitable period of time to allow healing, and control infection.

Cervical One-Third Root Fractures. These fractures are more complex and problematic,^{30,31,114} with a poorer prognosis. Cervical one-third root fractures often present as a crown segment dangling from lacerated, bloody gingival tissue (Figure 3C). Treatment for this injury includes cleaning the area with water or saline and repositioning the coronal tooth segment as quickly as possible. The tooth segment can be held in place with finger pressure, but the athlete should be referred to a dentist for definitive treatment that includes stabilization via a splint and long-term monitoring of pulp status.^{30,31}

Tooth Displacement Injuries. Tooth displacement injuries can be further categorized as concussions; subluxations; intrusive, lateral, or extrusive luxations (Figure 3D); or avulsions, which are also known as extra-articulations (Figure 3E). In general, tooth displacement injuries result from a traumatic force, which causes movement of the tooth within the alveolar bone.^{35,38,46} The direction and strength of the force contribute to the severity of the displacement and consequent damage. Pretrauma, a tooth is held in place within the alveolar bone. The PDL attaches the cementum on the root of the tooth to the alveolar bone in the tooth socket. Thus, depending on the direction and strength of the force, a displacement injury compresses and stretches the PDL and alveolar bone.^{29,34,115,116}

Tooth Concussions. A tooth that sustains a mild traumatic injury in the absence of a fracture or displacement is categorized as a tooth concussion,³⁸ which is not to be

confused with the brain injury of concussion. The concussed tooth may exhibit postimpact symptoms such as touch sensitivity. However, even mild injuries to a tooth can result in loss of pulp vitality or tooth loss in the future.

Subluxations. The mildest form of tooth displacement is a subluxation, in which the traumatized tooth maintains its position within the alveolar bone and exhibits minimal mobility. The only clinical sign may be minimal seepage of blood from the gingival sulcus surrounding the injured tooth.^{35,38} A subluxed tooth initially may exhibit postimpact tenderness, and warm salt water rinses may be beneficial.

Lateral and Extrusive Luxations. With a lateral luxation, an external force has displaced the tooth (buccally, lingually, distally, or mesially) so that it is out of normal position and deviated from its long axis (Figure 3D).^{35,38,117} Extruded teeth present with marked displacement and, depending on the severity of the luxation, may be misaligned yet not mobile.^{35,38,118,119} Treatment options will likely require repositioning and immobilization via placement of a semirigid, acid-etched composite resin or wire splint.^{33,35,38,117}

Intrusive Luxations. Intrusively luxated teeth are forced into their sockets in an axial (apical) direction (Figure 3D).^{33,35–38} If radiographs confirm that the root apex is fully formed, the dentist will reposition the tooth, place a splint, and determine the need for a root canal procedure. With an intruded immature tooth, the dentist may elect to watchfully wait for the tooth to re-erupt in conjunction with the continued development and maturation of the root apex.

Avulsions (Exarticulations). Avulsed teeth are completely removed from the alveolar socket (Figure 3E).^{46,47,120,121} Immediate onsite intervention by the AT or other health care provider is essential to enhance the probability of a successful clinical outcome. The avulsed tooth must first be located and replantation attempted within 5 minutes.^{29,46,111,112,120,122,123} To prevent additional trauma to the PDL, practitioners should refrain from handling the tooth by its root, as maintaining the viability of the PDL cells on the root surface is critical to a positive clinical outcome. Debris should never be brushed or scrubbed from the tooth, and the tooth should not be sterilized with boiling water or chemicals. If debris is visible on the tooth surface, the clinician can rinse the surface under the gentle flow of a liquid such as tepid water, milk, or physiologic saline. If the athlete is alert and oriented, replantation of the tooth can be attempted by inserting the root end into the socket and ensuring proper orientation of the tooth with the adjacent teeth. Once the tooth has been replanted, the athlete should bite down on a sterile gauze pad to stabilize the tooth and be immediately transported to a trauma-ready dentist for definitive treatment.⁴⁶ If the avulsed tooth cannot be replanted immediately and completely, the tooth should be submerged in a storage medium. Hanks' Balanced Salt Solution is the optimal storage medium for avulsed teeth. However, when ice is available for proper cooling, low-fat milk can serve as an alternative.^{48–54} Other less effective solutions are using saline or saliva or placing the avulsed tooth in the vestibule between the lips and teeth. Water should be avoided or used as the last option because it damages the PDL cells. Athletic trainers and other health care providers should always avoid transporting an avulsed tooth wrapped in dry gauze or a dry paper towel.

Role of a Properly Fitted Mouthguard. In a statement approved in 2010, the Academy for Sports Dentistry adopted the position that the single word “mouthguard” must be replaced by the phrase “a properly fitted mouthguard.”²² Furthermore, the statement identified key considerations for the properly fitted mouthguard, including but not limited to the following: (1) material meets approval of the US Food and Drug Administration, (2) fabricated over a stone model from an impression, (3) adequate thickness in all areas (eg, 3 mm in the occlusal area), and (4) regularly inspected under the supervision of a dentist.²² Most mouthguards worn by athletes during sports activities are the boil-and-bite types, which do not meet the definition of “properly fitted” as defined by the Academy. Furthermore, many researchers who examined the influence of mouthguards on orofacial injury focused on either stock or boil-and-bite mouthguards.¹² In some instances, the investigators included participants who used any mouthguard type.¹² Notably, when custom (ie, properly fitted) mouthguards were compared with other mouthguard types, injury rates did not differ.¹² This is likely because most commercially available (eg, boil-and-bite) and properly fitted (eg, custom) mouthguards are made of a similar ethylene vinyl acetate copolymer material.^{83–85} Although no superior protective benefit has been demonstrated, the properly fitted mouthguard can play an important role in perceived comfort.^{124,125} A properly fitted device can decrease discomfort and fatigue, which are often associated with mouthguard noncompliance.^{124,125} Therefore, if athletes report discomfort related to mouthguard use (stock or boil and bite), it may be beneficial to guide them toward a properly fitted mouthguard to increase compliance.

Mouthguard Classification Systems. In the United States, the most popular classification system is from the American Society for Testing and Materials (ASTM) International Designation: F 697-00 (2006) titled, “Standard Practice for Care and Use of Athletic Mouth Protectors.”²⁴ (Other classification systems exist in the United States and internationally [Table 3], but a complete comparison is beyond the scope of this position statement.) For the purposes of this position statement, we refer only to the ASTM classification system. Despite recommendations by sports dentists and other sports medicine professionals to use custom-fitted appliances, the stock (type III) and mouth-formed (type I, class 2) mouthguards are the most common appliances because of their low cost and wide availability. These appliances are defined as

- **Thermoplastic Vacuum Formed (Type I, Class 1).** Type I (class 1) and custom-made mouthguards (as well as laminated mouthguards) are the appliances recommended most often by clinicians. These custom mouthguards require fitting by a trained sports dentist. Impressions of the mouth are formed into stone casts, and ethylene vinyl acetate (EVA) materials or laminated combinations of EVA are thermoformed (via a vacuum or air pressure machine) over the mold to produce a congruently fitted mouthguard.
- **Thermoplastic Mouth Formed (Type I, Class 2).** These boil-and-bite mouthguards are advances over stock mouthguards in that they require some fitting to the user by heating and immediate wearing, which provides a minimal level of customization to the teeth and gums.

- **Thermosetting Mouth Formed (Type II, Class 1).** Thermosetting mouthguards are relatively new to the sports dental appliance culture. No commercially available thermosetting mouthguard appliances are available at the time of this writing.
- **Stock (Type III).** These appliances require no specialized fitting by the user. Off-the-shelf appliances that are simple semirigid trays that neither conform to nor are retained by the upper dentition, they are often the least expensive option for parents, coaches, and athletes.

International, National, and State Governing Rules

For each of its sanctioned high school sports, the NFHS publishes official rules books. These books provide comprehensive explanations of all aspects of the sport, including a common section on game and player equipment. When protective equipment such as a properly fitted mouthguard is required, the information is covered in this section of the rules book. In addition to these rules books, the NFHS also publishes a *Sports Medicine Handbook*,¹³ in its fourth edition at the time of this writing. Compiled by members of the NFHS Sports Medicine Advisory Committee, this handbook contains recommendations for administrators and sports medicine staff on best practices for preventing injuries in high school athletes. Procedures for the emergency management of dental injuries, as well as information on the importance of a properly fitted mouthguard, are contained in this handbook. Similarly, the NCAA has developed a manual of health guidelines for intercollegiate athletics programs, published annually as the *NCAA Sports Medicine Handbook*, most recently in its 24th edition.¹⁴ In the equipment section of this handbook, ATs can find a list of sports that mandate properly fitted mouthguards, as well as any position, color, or tooth coverage-based rule restrictions. For organized youth sports, ATs should refer to the protective equipment rules of each national governing body to determine best safety practices.

Mouthguard Effectiveness

Effectiveness of Mouthguards for Orofacial Injury. In the United States, Woodmansey¹⁶ reported that 39% of all dental injuries are sport related. A more recent study¹²⁶ of Taiwanese 15- to 18-year olds showed that sports and leisure activities accounted for 30.8% of traumatic dental injuries. In addition to the physical injury, the indirect costs of traumatic orofacial injury may have financial, psychological, and social consequences for participants and their families. Unfortunately, the true incidence of orofacial injury worldwide is difficult to establish due to varying access to and quality of health care, inconsistent definitions and reporting mechanisms, and limited quantitative data regarding mouthguard use and orofacial injury.^{12,127} In a systematic review of mouthguard use and injury (orofacial and concussion), Knapik et al¹² found that only 14 of 69 original research studies met the review criteria. Of the 14 investigations, only 1 was a prospective randomized control study⁶⁷; the remaining investigations involved nonrandomized or 1-group ecological interventions, prospective cohorts, or cross-sectional surveys. Based on post-1980 nonquestionnaire studies,

mouthguard nonusers were nearly 2 times more likely to suffer an orofacial injury than mouthguard users.¹²

Brain Concussion Risk-Reduction Effectiveness. The dentist for the Notre Dame University football team was one of the first individuals to illustrate through radiographic evidence that an intraoral appliance could change the temporomandibular joint relationship.^{128,129} More specifically, a 3-mm-thick intraoral appliance could separate the mandibular condyle from its fossa. This separation was posited to create a “recoil” space and is the basis for the hypothesis that 3-mm-thick intraoral appliances can attenuate transmitted forces to the cranial vault from a blow to the chin. Another historical and highly referenced study used to support the attenuation claim was conducted by Hickey et al,¹³⁰ who monitored intracranial pressure in cadavers after an impact to the chin. These historical studies have been criticized for their poor methodologic quality and a lack of the experimental rigor necessary for making causal inferences.⁷¹ In a more recent biomechanical investigation,³⁹ mouthguards were unlikely to absorb any significant amount of the kinetic energy transfer that is typical of helmet impacts resulting in concussion. In their systematic review, Knapik et al¹² found no evidence for using mouthguards as an effective risk-reduction strategy for concussion. Moreover, no sound clinical evidence has demonstrated the efficacy of mouthguards for preventing concussion. Therefore, these devices should not be recommended for this purpose.^{66,70,131}

Aerobic and Anaerobic Effectiveness. A logical concern associated with wearing a mouthguard is the effect the device has upon an athlete’s ability to breathe effectively and efficiently.^{132,133} Investigations into both airway dynamics and the physiologic effects of an array of mouthguards have been conducted.^{72–77} However, evidence for the effects of individual types is limited. Although airflow dynamics can be altered by mouthguards, compared with the no-mouthguard condition, the main physiologic variables were not negatively affected.^{72–77} Furthermore, several authors^{74,134,135} have suggested a positive influence of mouthguards upon physiologic factors during high-intensity bouts of exercise. Specifically, blood lactate levels decreased by up to 22% compared with no-mouthguard conditions and variables such as $\dot{V}O_2$, $\dot{V}O_2/\text{kg}$, and $\dot{V}CO_2$ improved. Mouthguard use in sport will continue to increase over time, so investigations into the effects of intraoral devices upon normal physiologic function need to continue and be expanded.

Effectiveness of Mandibular Orthopaedic Repositioning Appliances. Fabricating the oral appliance to reposition the mandible into a more kinesiologically appropriate posture has been suggested. To accomplish this, the appliance is fabricated so that the 3-dimensional maxillomandibular dimensions create a concentric circle on occlusion, a phenomenon known as *centric occlusion*. The premise is that perfect centric occlusion would cause the local jaw musculature to adapt physiologically and increase sensory input to the cerebral cortex, which would then facilitate increased performance on various tasks, including those that rely on vision, posture, balance, and motor skill.

In the mid-1980s, investigations of the potential effects of MORAs on appendicular musculoskeletal strength were

conducted.^{41–45,79,80} The past several decades have seen many attempts by basic scientists and clinicians to prove or disprove this hypothesis.^{41–45,136–138} These studies have been criticized as lacking true experimental designs, adequate sophistication of statistical analyses, and sufficient knowledge by the dental clinician researchers of how to test muscle strength. Thus, research in this area waned for several years until the mid-1990s and early 2000s, when Gelb et al^{43,44} and others^{134–137,139} investigated the effects of MORAs on additional human performance factors, including strength, posture, visual focusing, gas exchange, and lactate and cortisol levels. These studies produced largely equivocal results and were criticized for poor experimental methods; the only outcome that can be inferred is that MORA-type devices do not negatively affect human performance. As such, the devices are not recommended for improving ergogenic capabilities. In addition, although it is acceptable for athletes with a prognathic mandible or mandibular protrusion (or both) to use these devices, their efficacy in lowering the injury risk is unknown.

Mouthguard Material, Fabrication, and Care Considerations

Protective Mechanisms. A properly fitted mouthguard has been posited to protect against injury through at least 2 mechanisms: splinting and energy dissipation. *Splinting* (Figure 4) involves taking an initial focal impact force and redistributing it across a larger surface area of material. To accomplish this, a material needs to be stiff; however, if the material is too stiff, it is likely to be uncomfortable and contribute to noncompliance. Similarly, *energy dissipation* (Figure 5) is the ability of the material to deform with the impact and return to its normal shape while dissipating some of the energy. In a broader sense, we refer to these combined properties as a *viscoelastic response*. The term *viscous* indicates that a material deforms slowly when exposed to an external force.⁸³ The term *elastic* indicates that once a deforming force has been removed, the material will return to its original configuration.⁸³ The mechanical properties of viscoelastic materials are typically examined by means of stress-strain (or load-deformation) tests. During these tests, a viscoelastic material exhibits hysteresis loop behavior when the stress versus strain curves are superimposed. The area within the loop represents the energy lost due to heat dissipation, which in part explains why viscoelastic materials are good shock absorbers.⁸³

From a clinical standpoint, one of the most important properties of viscoelastic mouthguard materials is their ability to potentially reduce the magnitude of impact forces to the teeth by either absorbing the energy or lengthening the time of the impact event.⁸³ However, as the mouthguard material decelerates the impact event over the longer time period, the material has to travel (ie, compress) further and a bottoming-out phenomenon may occur. At the point where the material fully compresses (termed *densification*), there is an abrupt increase in force transmission to the tooth substrate, which may ultimately lead to injury.⁸³

Mouthguard Materials, Properties, and Processing. Mouthguards are formed from plastic materials. Most chemists and chemical engineers use the terms *plastics* and

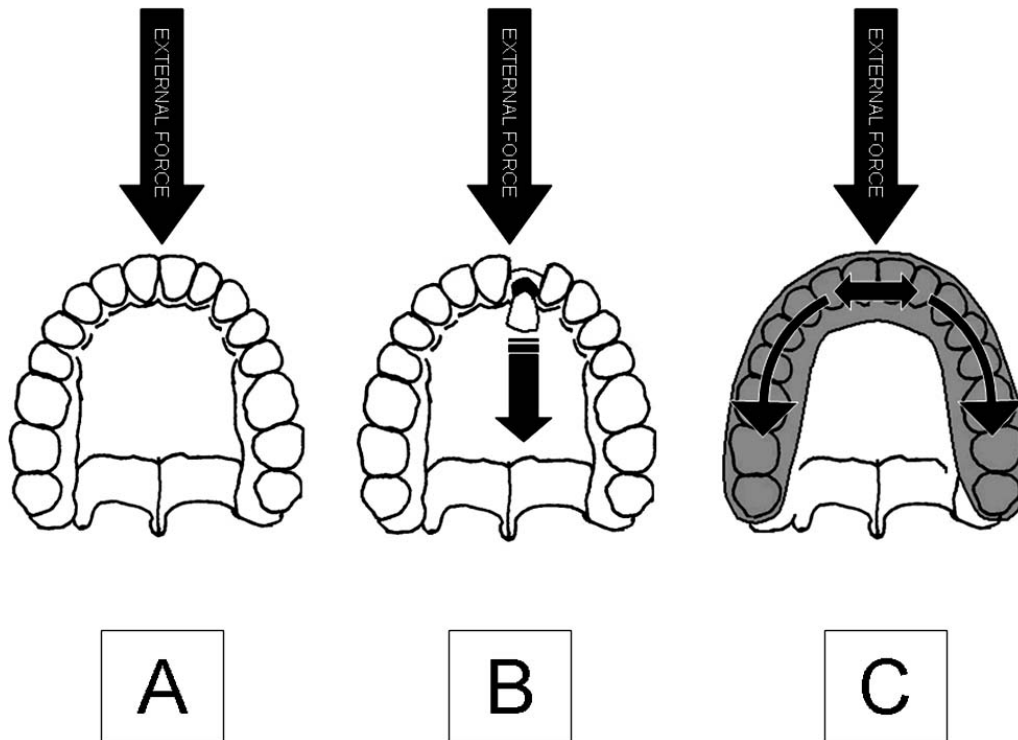


Figure 4. Illustration of mouthguard splinting mechanism. A, An external force is introduced to the unprotected (ie, no mouthguard) anterior aspect of the dentition. B, The external force focalizes at 1 point and transfers its momentum to the tooth-bone complex, causing fracture or luxation. C, With the mouthguard in place, the external force is diffused across the dentition, essentially “splinting” the teeth together. Reprinted from *Materials in Sports Equipment*, Vol. 2 (p. 134), A. Subic, 2007, Cambridge, England: CRC Press. Copyright 2007 by Woodhead Publishing Limited. Reprinted with permission.⁸³

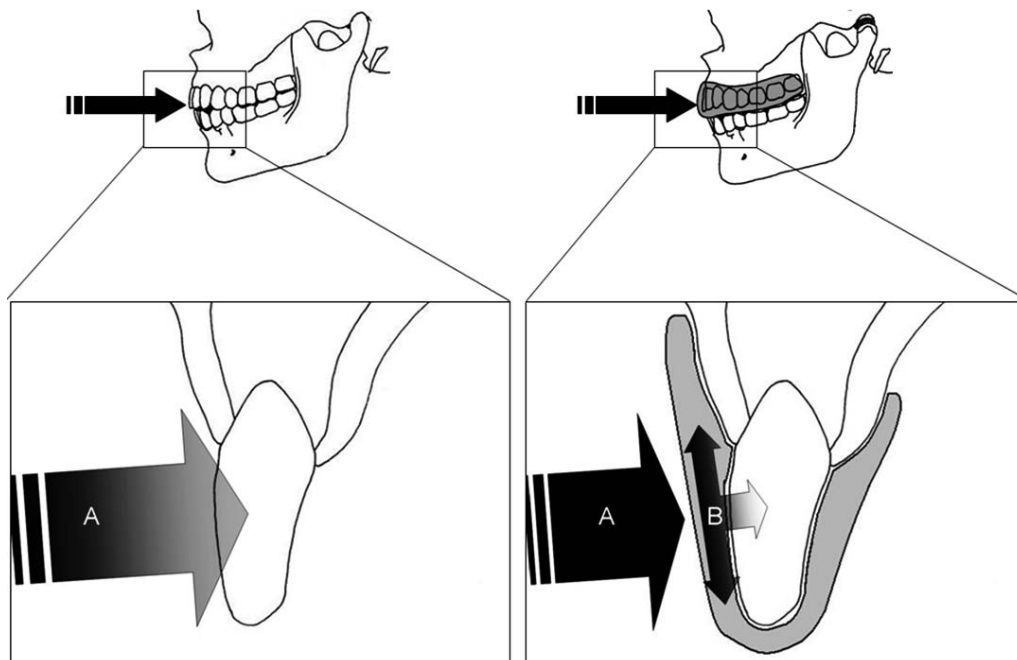


Figure 5. Illustration of mouthguard force-dissipation mechanism. Left: A, The external force is introduced to the unprotected anterior aspect of the tooth, resulting in complete transfer of momentum of motion. Right: A, The external force is directed at the protected anterior aspect of the tooth. B, The protective thickness of the mouthguard material compresses, dissipates a certain amount of energy as heat, and transfers the remaining energy to the substrate tooth. The same mechanism occurs when there is a violent contact to the tip of the teeth from a violent collision between the upper and lower dentitions. Reprinted from *Materials in Sports Equipment*, Vol. 2 (p. 134), A. Subic, 2007, Cambridge, England: CRC Press. Copyright 2007 by Woodhead Publishing Limited. Reprinted with permission.⁸³

polymers interchangeably. Polymers can be broadly categorized into 2 subcategories: (1) thermoplastics are 2-dimensional (ie, not cross-linked) molecules that can be softened by applying heat, reshaped, and returned to their original state by cooling; and (2) thermosetting plastics are 3-dimensional (ie, cross-linked) networked polymers that cannot be reshaped by heating. In an athletic training clinical setting, Orthoplast (Patterson Medical Holdings, Inc, Warrenville, IL) is an example of a thermoplastic material, whereas the rubber outer sole of an athletic shoe represents a thermosetting polymer. Currently, the majority of materials used for mouthguards, regardless of their class categorization (eg, boil-and-bite versus custom), are thermoplastic copolymers of EVA.

Several properties of polymers should be considered when choosing a material for a particular application. One of the most fundamental properties is glass transition temperature, T_g . Every plastic material has a temperature below which the polymer chains cease movement and the material exhibits “glassy” behavior. Conversely, above this temperature, the material has increased chain movement and exhibits “rubbery” behavior. A polymer material being used at its T_g exhibits “leathery,” or viscoelastic, behavior. At intraoral temperature, EVA copolymers are rubbery (ie, elastic) materials that are not optimal for mechanical damping. Regardless, EVA has many advantages (eg, low cost and easy fabrication) and will likely remain in abundant use until better materials are discovered.

To process EVA copolymers into mouthguards, the material is heated (usually in boiling water or near the heating element of a custom forming machine) above its crystalline melting temperature (T_m), which is typically 65°C to 70°C.⁸³ The exact melting temperature is determined by the vinyl acetate ratio in the copolymer (ie, the greater the vinyl acetate content, the lower the crystalline melting point). Once the EVA copolymer sample is heated above its melting point, crystalline regions (ie, physical cross-links) are no longer present, thereby removing the barrier to viscous melt flow.⁸³ At a critical temperature above the crystalline melting temperature, the EVA material reaches a softening point at which the melt strength is severely reduced. At this point, the EVA material begins to flow on a time scale that allows it to conform to the teeth (as in a boil-and-bite device) or over a positive mold of the teeth (as in a custom device).⁸³ After the heat source is removed, the temperature of the EVA material decreases below the crystalline freezing (T_c) point (typically 40°C to 50°C) and crystalline regions reform. This process “locks in” the newly formed structure of the mouthguard, thereby restoring the EVA material to the rubbery state and making it ready for end use.⁸³

Mouthguard-Fabrication Techniques. Mouth-formed mouthguards, as their name implies, rely upon the end user to place a moldable material into the mouth to create a final impression and fit. This technique improves on the fit and retention offered by basic nonmoldable mouthguard trays by accepting a basic impression of the dentition into the material. This type of device requires that the material be malleable while taking the impression but solidified during end use. The most common material for this application today is EVA, which is available in a broad range of compositions (ie, soft to hard). Placing the EVA in boiling water increases the material’s temperature and

softens it for molding. It is noteworthy to mention that, although EVA copolymers are historically the most widely used materials, other polyethylene blends, polycaprolactones, and propylene-based elastomers are gaining in popularity because of similar results: a softened, malleable material that can be fabricated. The softened mouthguard is placed on the dentition, and the user’s mouth is closed. Air is evacuated by sucking and biting down on the mouthguard, which allows the material to flow around the teeth and gums. Although mouth-formed mouthguards are the most common type in use today, user error during the formation process can lead to inconsistent thickness, fit, and retention.

The custom-fitted approach incorporates a dental model of the athlete’s teeth as the template for the molding process. The dental model is made from an impression of the teeth and dental arch. The impression is usually taken of the maxillary arch with an appropriate dental-impression material (eg, elastic algae-based product, such as alginate). If the athlete has a prognathic mandible or mandibular protrusion such that the mandibular teeth extend forward beyond the maxillary anterior teeth with both arches in occlusion, a mandibular impression may be used. The quality of the impression is the key to a satisfactory dental model and an appropriate custom mouthguard. An appropriate mouthguard cannot be fabricated if the impression does not have good internal definition, does not extend adequately beyond the teeth, does not register the soft tissues well, or becomes distorted, damaged, or torn. Therefore, the impression should be taken by a qualified dental professional. Once the negative impression is taken, a positive model of the teeth is made by pouring a hard-setting dental stone into the impression. The following custom fabrication techniques allow for a greater level of heating and pressure of the basic mouthguard material, which permits greater flow around the structures and ultimately provides a more accurate representation of the teeth, gums, and maxillary arch. Additionally, these techniques enable the dental professional to control the occlusal, labial, and palatal thicknesses of the mouthguard, as well as the smoothness of the edges and coverage of the intraoral structures.

For the vacuum-forming technique, a sheet of EVA is placed in a holding device in the forming machine, where it is softened using a heating element. Once melt-flow temperature is achieved, the material visually sags. The heat source is then removed and the softened material is lowered over the dental model. The sheet is drawn tightly over the teeth by a vacuum, resulting in an excellent internal adaptation. However, it is difficult to control material thickness, as this depends on operator-dependent factors such as material temperature and time in the vacuum. This technique can be used for laminating layers of material, but it is generally more difficult to perform and has less successful outcomes.

The pressure-laminate technique also involves placing a sheet of EVA in a holding device in the forming machine, where it is softened using a heating element. The material is heated as in the vacuum technique, but the softened mouthguard material is applied to a dental cast within a high-pressure chamber. Use of the pressure chamber results in much clearer and complete internal definition. Again, consistency of the end product is operator dependent, but

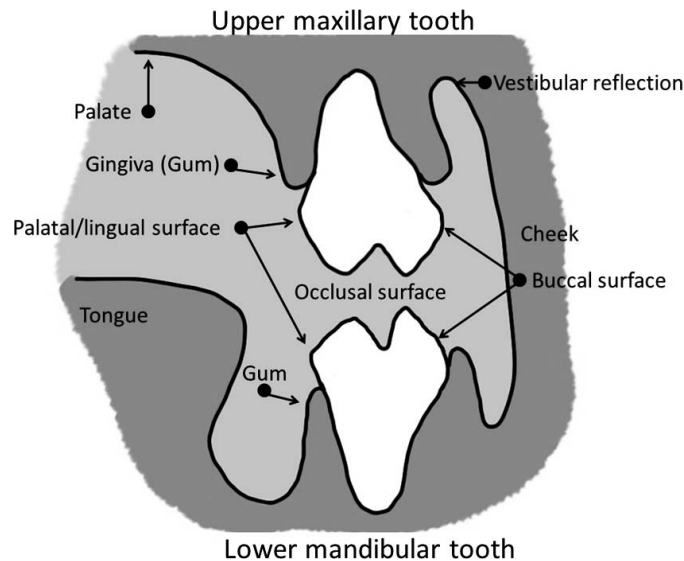


Figure 6. Illustration of basic tooth surfaces (left) and gingival anatomy (right) related to mouthguard fabrication. Adapted from “Mouthguards for use in sport and recreation—requirements and test methods,” by Technical Committee PH/3/11, 2001, *DD 253:2001*, p. 4-5. Copyright 2001 by the British Standards Institute.¹⁴⁰ Permission to reproduce extracts from British Standards is granted by BSI Standards Limited (BSI). No other use of this material is permitted. British Standards can be obtained in PDF or hard copy formats from the BSI online shop: www.bsigroup.com/shop or by contacting BSI Customer Services for hard copies only: Tel: +44 (0)845 086 9001, e-mail: cservices@bsigroup.com.

this technique allows multiple layers to be integrated into the mouthguard by laminating 1 sheet to another, thereby controlling appliance thickness.

Fit and Compliance. The athlete’s perceived comfort with the mouthguard is critical and of paramount importance for compliance. Noncompliance has been related to bulkiness, stability, hardness, dyspnea, speaking difficulty, oral dryness, and nausea.^{124,125} Custom-fabricated mouthguards that are individually crafted and adjusted by licensed dentists address the salient tooth surfaces (Figure 6) and coverage areas (Figure 7) and can

eliminate some of these problems. Adjustment may require the athlete to insert the mouthguard while the clinician checks the occlusion of the opposing arch for balance or premature contact. McClelland et al¹²⁵ noted that perceived comfort ratings of a mouthguard increased when the palatal peripheries were tapered and the labial and buccal peripheries were rounded. Tapering the palatal periphery controls the lingual bulk. Similarly, by shaping the margins, it is possible to improve comfort without sacrificing the device’s protective quality.

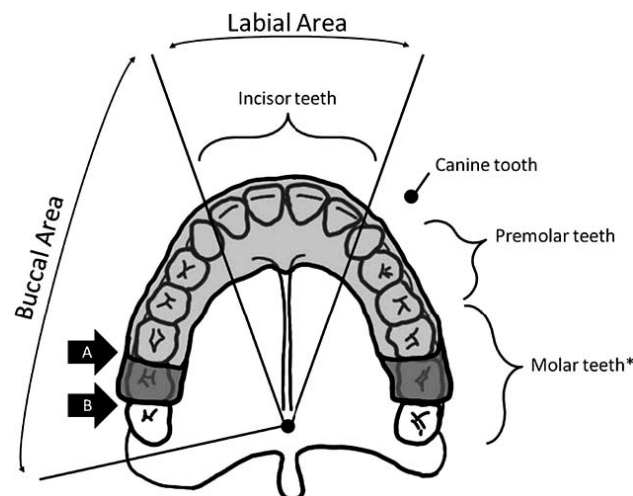


Figure 7. Recommended mouthguard-coverage areas. A, Coverage to the distal surface of the first molar for low-contact sports. B, Coverage to the distal surface of the second molars for high-contact sports. Note that the third molars are shown for completeness. However, in most individuals, these fail to erupt or have been removed, and therefore, the entire upper dentition will be covered for high-contact sports. The asterisk denotes that the third molars are shown for completeness. Adapted from “Mouthguards for use in sport and recreation—requirements and test methods,” by Technical Committee PH/3/11, 2001, *DD 253:2001*, p. 5. Copyright 2001 by the British Standards Institute.¹⁴⁰ Permission to reproduce extracts from British Standards is granted by BSI Standards Limited (BSI). No other use of this material is permitted. British Standards can be obtained in PDF or hard copy formats from the BSI online shop: www.bsigroup.com/shop or by contacting BSI Customer Services for hard copies only: Tel: +44 (0)845 086 9001, e-mail: cservices@bsigroup.com.

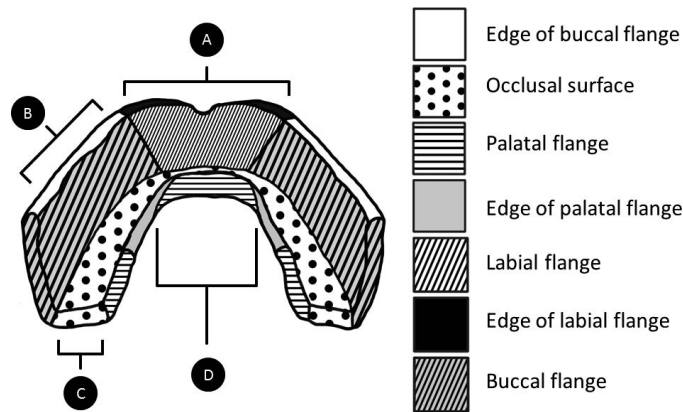


Figure 8. Generic mouthguard surface map corresponding to recommended clinical fabrication considerations listed in Table 5. A, labial area; B, buccal area; C, occlusal area; and D, palatal area. Recommended material thicknesses include labial aspect, 2–3 mm; occlusal aspect, 3 mm; palatal aspect, 2 mm. It is recommended that the labial flange extend to within 2 mm of the vestibular reflection. It is also recommended that the palatal flange extend 10 mm above the vestibular margin and the edges of the labial and palatal flanges be tapered in cross-section. Note: At least 1 study suggests that there is no additional shock-absorption protection afforded by extending the mouthguard onto the palate (Yamada J, Maeda Y, Satoh H, Miura J. Anterior palatal mouthguard margin location and its effect on shock-absorbing capability. *Dent Traumatol.* 2006;22(3):139–144⁸⁸).

A more detailed list of clinical mouthguard-fabrication specifications is located in Table 5. Visually, these mouthguard-fabrication specifications are represented in the mouthguard surface map illustrated in Figure 8. Unfortunately, use of these types of appliances is restricted by availability and expense. Most of the expense of custom-fabricated mouthguards is in the clinician's fabrication time and not in material costs. Although some research has established that mouthguards protect the teeth and mandible from injury, best practices regarding the fabrication process and materials have not been determined.

Performance Testing, Use, and Care. Only the American National Standards Institute/American Dental Association and Standards Australia International/Australian Dental Association provide guidelines that specifically describe the performance testing (ie, physical and mechanical properties) requirements that must be met by mouthguard material manufacturers. However, performance factors were based upon a single study of basic physical and mechanical properties of commercial EVA sheets and fabricated mouthguard specimens.⁸⁷ These properties and their performance thresholds are provided in Table 4. All measures except shock absorption were obtained at an approximate intraoral temperature of 37°C.

Cleaning, Maintenance, and Storage. With respect to cleaning, storage, and shipping, ASTM designation F697-06 provides general recommendations, including washing the mouthguard daily in cold or lukewarm water and using antimicrobial cleaning agents such as Listerine (Johnson & Johnson Consumer Inc, New Brunswick, NJ), Scope (Procter & Gamble, Cincinnati, OH), or Defense Sport Mouthguard Rinse (Sani Brands, Inc, Allentown, PA). When storing a thermoformable mouthguard, excessive heat should be avoided. The best recommendation for shipping a custom-made mouthguard is to fully seat the mouthguard on its dental stone model.

Suggested Best Practices

In most instances, an athlete will know that a dental injury has occurred. Once the injury is reported, the health care

provider should evaluate the intraoral location, as well as the type and severity of injury. The segment of permanent teeth most often affected by sport-related dental trauma contains the 6 maxillary anterior teeth (central incisors, lateral incisors, and canines); the central incisors are involved most frequently.¹⁴¹ Dental injuries may be classified as crown fractures, root fractures, or tooth-displacement injuries. Determining the extent and severity of the dental injury will better enable the onsite AT to recognize and manage the condition. Subjective symptoms reported by the injured athlete are beneficial in establishing the diagnosis. For example, an athlete who reports that a tooth is sensitive to air, cold, or touch likely has a crown fracture that extends beyond the outer enamel into the underlying dentin of a vital tooth. In contrast, constant, piercing, or throbbing pain suggests more severe and often irreversible damage to the dental pulp.

Additional diagnostic adjuncts can be used by the AT to facilitate triage of patients with dental injuries. A pocket flashlight can be used for visual examination to identify fractures, displacements, bite (occlusal) disturbances, soft tissue edema, or hemorrhage. Transillumination of the traumatized tooth will aid in identifying enamel prism damage (infractures) in the absence of an overt fracture. This technique is typically performed in a darkened room with a bright light directed at the tooth to locate infractures and fractures, which present as dark areas or lines. Transillumination can also identify tooth crown discoloration caused by hemorrhage from the pulp exuding into the dentin tubules. Palpation of the traumatized tooth using proper barrier protection can provide valuable information regarding displacement and mobility. When considered together, these individual diagnostic procedures supply the care provider with a more comprehensive assessment to properly triage the injured athlete. Hence, triage for a sport-related dental injury may range from no immediate response indicated to onsite temporary intervention with subsequent referral for dental follow up to immediate transport to a trauma-ready dentist or emergency facility for definitive management.

The importance of the orofacial region as an integral component of the overall cranial complex cannot be overemphasized. As such, to assess the likelihood of a concussion, clinicians are advised to perform a rapid neurologic screening on athletes who have sustained any sport-related traumatic dental injury. The injured athlete can then be triaged accordingly.^{142,143} In most instances, the health care professional will know or have access to the patient's medical history and general health status, such as tetanus immunization status. For clean minor wounds, a tetanus booster is recommended when the time since the last booster exceeds 10 years. When the wound has been contaminated, a booster is recommended if the time since the last booster exceeds 5 years. If the athlete had not previously received the complete regimen, tetanus immune globulin may be required.¹⁹ Antibiotics, oral disinfectant rinses (eg, oral chlorhexidine), or both may be prescribed by the attending dentist for an athlete who has sustained an avulsed tooth, an alveolar bone fracture, a maxillary or mandibular jaw fracture, or a soft tissue through-and-through laceration.

Athletic trainers and others providing onsite care to athletes should take the lead in recommending the appointment of sports dentists to their sports medicine teams.¹⁴⁴ Team dentists can be tasked with fabricating custom mouthguards, assembling the contents for a dental emergency kit, and expeditiously managing sport-related traumatic dental injuries. At the very least, the AT should develop a list of available dentists for consultations and referrals. Return-to-play decisions after sport-related traumatic dental injuries should be conducted in consultation with the attending dentist.^{145–148}

ACKNOWLEDGMENTS

We gratefully acknowledge the efforts of Randall Cohen, DPT, ATC; Michael Higgins, PhD, PT, ATC, CSCS; Paul Nativi, DMD; John Reynolds, MS, VATL, ATC; Mark Roettger, DDS, FASD; Leslie Rye, DDS, FAGD, FASD, FICD; and the Pronouncements Committee in the preparation of this document.

DISCLAIMER

The NATA and NATA Foundation publish position statements as a service to promote the awareness of certain issues to their members. The information contained in the position statement is neither exhaustive nor exclusive to all circumstances or individuals. Variables such as institutional human resource guidelines, state or federal statutes, rules, or regulations, as well as regional environmental conditions, may impact the relevance and implementation of these recommendations. The NATA and NATA Foundation advise members and others to carefully and independently consider each of the recommendations (including the applicability of same to any particular circumstance or individual). The position statement should not be relied upon as an independent basis for care but rather as a resource available to NATA members or others. Moreover, no opinion is expressed herein regarding the quality of care that adheres to or differs from NATA and NATA Foundation position statements. The NATA and NATA Foundation reserve the right to rescind or modify its position statements at any time.

REFERENCES

1. US Department of Health and Human Services. *Oral Health in America: A Report of the Surgeon General*. Rockville, MD: National Institute of Dental and Craniofacial Research, National Institutes of Health; 2000.
2. Kvittum B, Hardie NA, Roettger M, Conry J. Incidence of orofacial injuries in high school sports. *J Public Health Dent*. 1998;58(4):288–293.
3. Kumamoto DP, Maeda Y. A literature review of sports-related orofacial trauma. *Gen Dent*. 2004;52(3):270–280.
4. National Federation of State High School Associations. *NFHS 2003–04 High School Athletics Participation Survey*. Indianapolis, IN: National Federation of State High School Associations; 2004.
5. National Collegiate Athletic Associations. *1981–82 to 2004–05 NCAA Sports Sponsorship and Participation Rates Report*. Vol 2004. Indianapolis, IN: National Collegiate Athletic Associations; 2006.
6. Emergency treatment of athletic dental injuries. Academy for Sports Dentistry Web site. <http://www.academyforsportsdentistry.org/treatment-cards>. Accessed October 9, 2015.
7. Dental trauma guidelines (Revised 2012). International Association of Dental Traumatology Web site. <http://www.iadt-dentaltrauma.org/1-9%20%20iadt%20guidelines%20combined%20-%201r%20-%2011-5-2013.pdf>. Accessed October 9, 2015.
8. DiAngelis AJ, Andreasen JO, Ebeleseder KA, et al. International Association of Dental Traumatology guidelines for the management of traumatic dental injuries: 1, fractures and luxations of permanent teeth. *Dent Traumatol*. 2012;28(1):2–12.
9. Andersson L, Andreasen JO, Day P, et al. International Association of Dental Traumatology guidelines for the management of traumatic dental injuries: 2, avulsion of permanent teeth. *Dent Traumatol*. 2012;28(2):88–96.
10. Malmgren B, Andreasen JO, Flores MT, et al. International Association of Dental Traumatology guidelines for the management of traumatic dental injuries: 3, injuries in the primary dentition. *Dent Traumatol*. 2012;28(3):174–182.
11. The dental trauma guide. The International Association of Dental Traumatology Web site. <http://www.dentaltraumaguide.org>. Accessed October 9, 2015.
12. Knapik JJ, Marshall SW, Lee RB, et al. Mouthguards in sport activities: history, physical properties, and injury prevention effectiveness. *Sports Med*. 2007;37(2):117–144.
13. National Federation of State High School Associations. *Sports Medicine Handbook*. 4th ed. Indianapolis, IN: National Federation of State High School Associations; 2011.
14. Klossner D, ed. *2013–14 NCAA Sports Medicine Handbook*. 24th ed. Indianapolis, IN: The National Collegiate Athletics Association; 2013.
15. Gutmann JL, Gutmann MS. Cause, incidence, and prevention of trauma to teeth. *Dent Clin North Am*. 1995;39(1):1–13.
16. Woodmansey KF. Athletic mouth guards prevent orofacial injury. *J Am Coll Health*. 1997;45(4):179–182.
17. Ebell MH, Siwek J, Weiss BD, et al. Strength of Recommendation Taxonomy (SORT): a patient-centered approach to grading evidence in the medical literature. *Am Fam Physician*. 2004;69(3):548–556.
18. Andersen JC, Courson RW, Kleiner DM, McLoda TA. National Athletic Trainers' Association position statement: emergency planning in athletics. *J Athl Train*. 2002;37(1):99–104.
19. Ranalli DN, Demas PN. Orofacial injuries from sport: preventive measures for sports medicine. *Sports Med*. 2002;32(7):409–418.
20. Policy on prevention of sports-related orofacial injuries. American Academy of Pediatric Dentistry Web site. http://www.aapd.org/media/policies_guidelines/p_sports.pdf. Accessed October 9, 2015.
21. Broglio SP, Cantu RC, Gioia GA, et al. National Athletic Trainers' Association position statement: management of sport concussion. *J Athl Train*. 2014;49(2):245–265.
22. A properly fitted mouthguard. Academy for Sports Dentistry Web site. <http://www.academyforsportsdentistry.org/position-statement>. Accessed October 9, 2015.

23. ADA statement on athletic mouthguards. American Dental Association Web site. <http://www.ada.org/en/member-center/oral-health-topics/mouthguards>. Published 2009. Accessed November 20, 2013.
24. Revision of F697-00 (2006): standard practice for care and use of athletic mouth protectors. American Society for Testing and Materials (ASTM) International Web site. <http://www.astm.org/DATABASE.CART/WORKITEMS/WK37941.htm>. Accessed October 9, 2015.
25. ANSI/ADA Standard No. 99. Athletic mouth protectors and materials: 2001 (reaffirmed 2013). American Dental Association Web site. <http://www.ada.org/en/science-research/dental-standards/dental-products/products-standards-technical-specifications-and-technical-reports>. Accessed October 12, 2015.
26. The fabrication, use and maintenance of sports mouthguards. Australian Dental Association Web site. http://www.ada.org.au/app_cmslib/media/lib/1304/m574050_v1_mouthguard%20handbook%20.pdf. Accessed October 12, 2015.
27. Ranalli DN. Dental injuries in sports. *Curr Sports Med Rep*. 2005;4(1):12–17.
28. National Federation of State High School Associations. *Sports Medicine Handbook*. 3rd ed. Indianapolis, IN: National Federation of State High School Associations; 2008.
29. Andreasen JO, Andreasen FM, Skeie A, Hjorting-Hansen E, Schwartz O. Effect of treatment delay upon pulp and periodontal healing of traumatic dental injuries—a review article. *Dent Traumatol*. 2002;18(3):116–128.
30. Flores MT, Andreasen JO, Bakland LK, et al. Guidelines for the evaluation and management of traumatic dental injuries. *Dent Traumatol*. 2001;17(1):1–4.
31. Flores MT, Andreasen JO, Bakland LK, et al. Guidelines for the evaluation and management of traumatic dental injuries. *Dent Traumatol*. 2001;17(3):97–102.
32. Ravn JJ. Follow-up study of permanent incisors with enamel fractures as a result of an acute trauma. *Scand J Dent Res*. 1981;89(3):213–217.
33. Humphrey J, Kenny D, Barrett E. Clinical outcomes for permanent incisor luxations in a pediatric population. I. Intrusions. *Dent Traumatol*. 2003;19(5):266–273.
34. Andreasen FM, Andreasen JO. Diagnosis of luxation injuries: the importance of standardized clinical, radiographic and photographic techniques in clinical investigations. *Endod Dent Traumatol*. 1985;1(5):160–169.
35. Flores MT, Andreasen JO, Bakland LK, et al. Guidelines for the evaluation and management of traumatic dental injuries. *Dent Traumatol*. 2001;17(4):145–148.
36. Al-Badri S, Kinirons M, Cole B, Welbury R. Factors affecting resorption in traumatically intruded permanent incisors in children. *Dent Traumatol*. 2002;18(2):73–76.
37. Andreasen JO, Bakland LK, Andreasen FM. Traumatic intrusion of permanent teeth. Part 3: a clinical study of the effect of treatment variables such as treatment delay, method of repositioning, type of splint, length of splinting and antibiotics on 140 teeth. *Dent Traumatol*. 2006;22(2):99–111.
38. Flores MT, Andreasen JO, Bakland LK, et al. Guidelines for the evaluation and management of traumatic dental injuries. *Dent Traumatol*. 2001;17(2):49–52.
39. Viano DC, Withnall C, Wonnacott M. Effect of mouthguards on head responses and mandible forces in football helmet impacts. *Ann Biomed Eng*. 2012;40(1):47–69.
40. Pae A, Yoo RK, Noh K, Paek J, Kwon KR. The effects of mouthguards on the athletic ability of professional golfers. *Dent Traumatol*. 2013;29(1):47–51.
41. Burkett LN, Bernstein AK. Strength testing after jaw repositioning with a mandibular orthopedic appliance. *Physician Sportsmed*. 1982;10(2):101–107.
42. Chiodo GT, Rosenstein DI. Mandibular orthopedic repositioning appliance and athletic performance. *J Oreg Dent Assoc*. 1986;56(2):31–33.
43. Gelb H, Mehta NR, Forgione AG. Relationship of muscular strength to jaw posture in sports dentistry. *N Y State Dent J*. 1995;61(9):58–66.
44. Gelb H, Mehta NR, Forgione AG. The relationship between jaw posture and muscular strength in sports dentistry: a reappraisal. *Cranio*. 1996;14(4):320–325.
45. Moore TJ, Santa Maria DL, Hatfield BD, Ryder MN, Weiner LB. The mandibular orthopedic repositioning appliance and its effect on power production in conditioned athletes. *Physician Sportsmed*. 1986;14(12):137–139,142–145.
46. Flores MT, Andreasen JO, Bakland LK, et al. Guidelines for the evaluation and management of traumatic dental injuries. *Dent Traumatol*. 2001;17(5):193–198.
47. Trope M. Clinical management of the avulsed tooth: present strategies and future directions. *Dent Traumatol*. 2002;18(1):1–11.
48. Harkacz OM, Carnes DL, Walker WA. Determination of periodontal ligament cell viability in oral rehydration fluid, Gatorade, and milks of varying fat content. *J Endod*. 1997;23(11):687–690.
49. Hiltz J, Trope M. Vitality of human lip fibroblasts in milk, Hanks balanced salt solution and Viaspan storage media. *Endod Dent Traumatol*. 1991;7(2):69–72.
50. Kenny DJ, Barrett EJ. Recent developments in dental traumatology. *Pediatr Dent*. 2001;23(6):464–468.
51. Krasner P. Modern treatment of avulsed teeth by emergency physicians. *Am J Emerg Med*. 1994;12(2):241–246.
52. Krasner P, Rankow HJ. New philosophy for the treatment of avulsed teeth. *Oral Surg Oral Med Oral Pathol Oral Radiol Endod*. 1995;79(5):616–623.
53. Pohl Y, Filippi A, Kirschner H. Results after replantation of avulsed permanent teeth. II: periodontal healing and the role of physiologic storage and antiresorptive-regenerative therapy. *Dent Traumatol*. 2005;21(2):93–101.
54. Sigalas E, Regan JD, Kramer PR, Witherspoon DE, Opperman LA. Survival of human periodontal ligament cells in media proposed for transport of avulsed teeth. *Dent Traumatol*. 2004;20(1):21–28.
55. Quarrie KL, Gianotti SM, Chalmers DJ, Hopkins WG. An evaluation of mouthguard requirements and dental injuries in New Zealand rugby union. *Br J Sports Med*. 2005;39(9):650–651.
56. Marshall SW, Loomis DP, Waller AE, et al. Evaluation of protective equipment for prevention of injuries in rugby union. *Int J Epidemiol*. 2005;34(1):113–118.
57. Cohen A. A five year comparative study of various mouth protectors. *J Sch Health*. 1963;33:83–85.
58. Cohen A, Borish AL. Mouth protector project for football players in Philadelphia high schools. *J Am Dent Assoc*. 1958;56(6):863–864.
59. Cohen A, Borish AL. A four year comparative study of various mouth protectors. *Bull Nat Assoc Secondar Sch Princip*. 1961;45:145–148.
60. Dunbar DM. Report on reduction in mouth injuries. *J Mass Dent Soc*. 1962;11:31, 34–35.
61. Moon DG, Mitchell DF. An evaluation of a commercial protective mouthpiece for football players. *J Am Dent Assoc*. 1961;62:568–572.
62. Schoen GH. Report of committee on mouth protector project. *Bull Nassau County Dent Soc*. 1956;30:12–14.
63. Blignaut JB, Carstens IL, Lombard CJ. Injuries sustained in rugby by wearers and non-wearers of mouthguards. *Br J Sports Med*. 1987;21(2):5–7.
64. McNutt T, Shannon SW, Wright JT, Feinstein RA. Oral trauma in adolescent athletes: a study of mouth protectors. *Pediatr Dent*. 1989;11(3):209–213.

65. Maestrello-deMoya MG, Primosch RE. Orofacial trauma and mouth-protector wear among high school varsity basketball players. *ASDC J Dent Child*. 1989;56(1):36–39.
66. Labella CR, Smith BW, Sigurdsson A. Effect of mouthguards on dental injuries and concussions in college basketball. *Med Sci Sports Exerc*. 2002;34(1):41–44.
67. Finch C, Braham R, McIntosh A, McCrory P, Wolfe R. Should football players wear custom fitted mouthguards? Results from a group randomised controlled trial. *Inj Prev*. 2005;11(4):242–246.
68. dela Cruz GG, Knapik JJ, Birk MG. Evaluation of mouthguards for the prevention of orofacial injuries during United States Army basic military training. *Dent Traumatol*. 2008;24(1):86–90.
69. Sports Medicine Advisory Committee. Position statement and recommendations for mouthguard use in sports. National Federation of State High School Associations Web site. <http://www.nfhs.org/media/1014750/mouthguard-nfhs-smac-position-statement-october-2014.pdf>. Updated October 2014. Accessed October 12, 2015.
70. McCrory P, Meeuwisse WH, Aubry M, et al. Consensus statement on concussion in sport: the 4th International Conference on Concussion in Sport held in Zurich, November 2012. *Br J Sports Med*. 2013;47(5):250–258.
71. McCrory P. Do mouthguards prevent concussion? *Br J Sports Med*. 2001;35(2):81–82.
72. Bourdin M, Brunet-Patru I, Hager P, et al. Influence of maxillary mouthguards on physiological parameters. *Med Sci Sports Exerc*. 2006;38(8):1500–1504.
73. Amis T, Di Somma E, Bacha F, Wheatley J. Influence of intra-oral maxillary sports mouthguards on the airflow dynamics of oral breathing. *Med Sci Sports Exerc*. 2000;32(2):284–290.
74. Francis KT, Brasher J. Physiological effects of wearing mouthguards. *Br J Sports Med*. 1991;25(4):227–231.
75. Kececi AD, Cetin C, Eroglu E, Baydar ML. Do custom-made mouth guards have negative effects on aerobic performance capacity of athletes? *Dent Traumatol*. 2005;21(5):276–280.
76. Duarte-Pereira DM, Del Rey-Santamaria M, Javierre-Garces C, et al. Wearability and physiological effects of custom-fitted vs. self-adapted mouthguards. *Dent Traumatol*. 2008;24(4):439–442.
77. Delaney JS, Montgomery DL. Effect of noncustom bimolar mouthguards on peak ventilation in ice hockey players. *Clin J Sport Med*. 2005;15(3):154–157.
78. Duddy FA, Weissman J, Lee RA, Paranjpe A, Johnson JD, Cohenca N. Influence of different types of mouthguards on strength and performance of collegiate athletes: a controlled-randomized trial. *Dent Traumatol*. 2012;28(4):263–267.
79. Schubert MM, Guttu RL, Hunter LH, Hall R, Thomas R. Changes in shoulder strength and leg strength in athletes wearing mandibular orthopedic repositioning appliances. *J Am Dent Assoc*. 1984;108(3):334–337.
80. Yates JW, Koen TJ, Semenick DM, Kuftinec MM. Effect of a mandibular orthopedic repositioning appliance on muscular strength. *J Am Dent Assoc*. 1984;108(3):331–333.
81. Kang KW, Lee SW. The effects of mandibular orthopedic repositioning appliance (MORA) on back muscle strength and attention focusing. *J Dent Coll Seoul Natl Univ*. 1988;12:217–230.
82. Tsukimura N. Study on the relation between the stomatognathic system and systemic condition—influences of postural changes in vertical maxillomandibular relation on back strength. *J Japan Prosthodontic Soc*. 1992;36(4):705–719.
83. Gould TE, Piland SG, Hoyle CE, Nazarenko S. Mouth protection in sports. In: Subic A, ed. *Materials in Sports Equipment*. Vol 2. Cambridge, England: Woodhead Publishing Limited; 2007.
84. Gould TE, Piland SG, Shin J, Hoyle CE, Nazarenko S. Characterization of mouthguard materials: physical and mechanical properties of commercialized products. *Dent Mater*. 2009;25(6):771–780.
85. Gould TE, Piland SG, Shin J, McNair O, Hoyle CE, Nazarenko S. Characterization of mouthguard materials: thermal properties of commercialized products. *Dent Mater*. 2009;25(12):1593–1602.
86. Craig RG, Godwin WC. Physical properties of materials for custom-made mouth protectors. *J Mich State Dent Assoc*. 1967;49(2):34–40.
87. Craig RG, Godwin WC. Properties of athletic mouth protectors and materials. *J Oral Rehabil*. 2002;29(2):146–150.
88. Yamada J, Maeda Y, Satoh H, Miura J. Anterior palatal mouthguard margin location and its effect on shock-absorbing capability. *Dent Traumatol*. 2006;22(3):139–144.
89. American Academy on Pediatric Dentistry Clinical Affairs Committee, American Academy on Pediatric Dentistry Council on Clinical Affairs. Policy on prevention of sports-related orofacial injuries. *Pediatr Dent*. 2009;30(suppl 7):58–60.
90. Ranalli DN. Sports dentistry and dental traumatology. *Dent Traumatol*. 2002;18(5):231–236.
91. Pierdomenic L, Bonsi L, Calvitti M, et al. Multipotent mesenchymal stem cells with immunosuppressive activity can be easily isolated from dental pulp. *Transplantation*. 2005;80(6):836–842.
92. Heyeraas KJ, Sveen OB, Mjor IA. Pulp-dentin biology in restorative dentistry. Part 3: pulpal inflammation and its sequelae. *Quintessence Int*. 2001;32(8):611–625.
93. Ravn JJ. Follow-up study of permanent incisors with enamel cracks as a result of acute trauma. *Scand J Dent Res*. 1981;89(2):117–123.
94. Donley KJ. Management of sports-related crown fractures. *Dent Clin North Am*. 2000;44(1):85–94.
95. Lambert DL. Conservative aesthetic solutions for the adolescent and young adult utilizing composite resins. *Dent Clin North Am*. 2006;50(1):87–118.
96. Ravn JJ. Follow-up study of permanent incisors with enamel-dentin fractures after acute trauma. *Scand J Dent Res*. 1981;89(5):355–365.
97. Chu FC, Yim TM, Wei SH. Clinical considerations for reattachment of tooth fragments. *Quintessence Int*. 2000;31(6):385–391.
98. Maia EA, Baratieri LN, de Andrada MA, Monteiro S Jr, de Araujo EM Jr. Tooth fragment reattachment: fundamentals of the technique and two case reports. *Quintessence Int*. 2003;34(2):99–107.
99. Pagliarini A, Rubini R, Rea M, Campese M. Crown fractures: effectiveness of current enamel-dentin adhesives in reattachment of fractured fragments. *Quintessence Int*. 2000;31(2):133–136.
100. Diangelis AJ, Bakland LK. Traumatic dental injuries: current treatment concepts. *J Am Dent Assoc*. 1998;129(10):1401–1414.
101. Olsburgh S, Jacoby T, Krejci I. Crown fractures in the permanent dentition: pulpal and restorative considerations. *Dent Traumatol*. 2002;18(3):103–115.
102. Andersson L, Emani-Kristiansen Z, Hogstrom J. Single-tooth implant treatment in the anterior region of the maxilla for treatment of tooth loss after trauma: a retrospective clinical and interview study. *Dent Traumatol*. 2003;19(3):126–131.
103. Jackson NG, Waterhouse PJ, Maguire A. Factors affecting treatment outcomes following complicated crown fractures managed in primary and secondary care. *Dent Traumatol*. 2006;22(4):179–185.
104. Mjor IA. Pulp-dentin biology in restorative dentistry. Part 7: the exposed pulp. *Quintessence Int*. 2002;33(2):113–135.
105. Rafter M. Apexification: a review. *Dent Traumatol*. 2005;21(1):1–8.
106. Andreasen JO, Andreasen FM, Mejare I, Cvek M. Healing of 400 intra-alveolar root fractures. 2. Effect of treatment factors such as treatment delay, repositioning, splinting type and period and antibiotics. *Dent Traumatol*. 2004;20(4):203–211.
107. Andreasen JO, Andreasen FM, Mejare I, Cvek M. Healing of 400 intra-alveolar root fractures. 1: Effect of pre-injury and injury factors such as sex, age, stage of root development, fracture type, location of fracture and severity of dislocation. *Dent Traumatol*. 2004;20(4):192–202.

108. Cvek M, Andreasen JO, Borum MK. Healing of 208 intra-alveolar root fractures in patients aged 7–17 years. *Dent Traumatol.* 2001;17(2):53–62.
109. Feely L, Mackie IC, Macfarlane T. An investigation of root-fractured permanent incisor teeth in children. *Dent Traumatol.* 2001;19(1):52–54.
110. Cvek M, Mejare I, Andreasen JO. Conservative endodontic treatment of teeth fractured in the middle of apical part of the root. *Dent Traumatol.* 2004;20(5):261–269.
111. Andreasen JO, Borum MK, Jacobsen HL, Andreasen FM. Replantation of 400 avulsed permanent incisors, 2: factors related to pulpal healing. *Endod Dent Traumatol.* 1995;11(2):59–68.
112. Andreasen JO, Borum MK, Jacobsen HL, Andreasen FM. Replantation of 400 avulsed permanent incisors, 4: factors related to periodontal ligament healing. *Endod Dent Traumatol.* 1995;11(2):76–89.
113. Camp JH. Management of sports-related root fractures. *Dent Clin North Am.* 2000;44(1):95–109.
114. Cvek M, Mejare I, Andreasen JO. Healing and prognosis of teeth with intra-alveolar fractures involving the cervical part of the root. *Dent Traumatol.* 2002;18(2):57–65.
115. Andreasen FM, Pedersen BV. Prognosis of luxated permanent teeth: the development of pulp necrosis. *Endod Dent Traumatol.* 1985;1(6):207–220.
116. Crona-Larsson G, Bjarnason S, Noren J. Effect of luxation injuries on permanent teeth. *Endod Dent Traumatol.* 1991;7(5):199–206.
117. Nikoui M, Kenny DJ, Barrett EJ. Clinical outcomes for permanent incisor luxations in a pediatric population. III. Lateral luxations. *Dent Traumatol.* 2003;19(5):280–285.
118. Humphreys K, Al Badri S, Kinirons M, et al. Factors affecting outcomes of traumatically extruded permanent teeth in children. *Pediatr Dent.* 2003;25(5):475–478.
119. Lee R, Barrett EJ, Kenny DJ. Clinical outcomes for permanent incisor luxations in a pediatric population, II: extrusions. *Dent Traumatol.* 2003;19(5):274–279.
120. American Association of Endodontists. Treatment of the avulsed permanent tooth: recommended guidelines of the American Association of Endodontists. *Dent Clin North Am.* 1995;39(1):221–225.
121. Barrett EJ, Kenny DJ. Avulsed permanent teeth: a review of the literature and treatment guidelines. *Endod Dent Traumatol.* 1997;13(4):153–163.
122. Barrett EJ, Kenny DJ, Tennenbaum HC, Sigal MJ, Johnston DH. Replantation of permanent incisors in children using Emdogain. *Dent Traumatol.* 2005;21(5):269–275.
123. Barrett EJ, Kenny DJ. Survival of avulsed permanent maxillary incisors in children following delayed replantation. *Endod Dent Traumatol.* 1997;13(6):269–275.
124. Brionnet JM, Roger-Leroi V, Tubert-Jeannin S, Garson A. Rugby players' satisfaction with custom-fitted mouthguards made with different materials. *Community Dent Oral Epidemiol.* 2001;29:234–238.
125. McClelland C, Kinirons M, Geary L. A preliminary study of patient comfort associated with customized mouth guards. *Br J Sports Med.* 1999;33(3):186–189.
126. Huang B, Marcenes W, Croucher R, Hector M. Activities related to the occurrence of traumatic dental injuries in 15- to 18-year-olds. *Dent Traumatol.* 2009;25(1):64–68.
127. Bastone EB, Freer TJ, McNamara JR. Epidemiology of dental trauma: a review of the literature. *Aust Dent J.* 2000;45(1):2–9.
128. Stenger JM, Lawson EA, Wright JM, Ricketts J. Mouthguards: protection against shock to the head, neck and teeth. *J Am Dent Assoc.* 1964;69:273–281.
129. Stenger JM. Physiologic dentistry with Notre Dame athletes. *Basal Facts.* 1977;2(1):8–18.
130. Hickey JC, Morris AL, Carlson LD, Seward TE. The relation of mouth protectors to cranial pressure and deformation. *J Am Dent Assoc.* 1967;74(4):735–740.
131. Wisniewski JF, Guskiewicz K, Trope M, Sigurdsson A. Incidence of cerebral concussion associated with type of mouthguard used in college football. *Dent Traumatol.* 2004;20(3):143–149.
132. Cornwell H, Messer LB, Speed H. Use of mouthguards by basketball players in Victoria, Australia. *Dent Traumatol.* 2003;19(4):193–203.
133. Kerr IL. Mouth guards for the prevention of injuries in contact sports. *Sports Med.* 1986;3(6):415–427.
134. Garner DP, Dudgeon WD, Scheett TP, McDivitt EJ. The effects of mouthpiece use on gas exchange parameters during steady-state exercise in college-aged men and women. *J Am Dent Assoc.* 2011;142(9):1041–1047.
135. Garner DP, McDivitt E. Effects of mouthpiece use on airway openings and lactate levels in healthy college males. *Compend Contin Educ Dent.* 2009;30 Spec 2:9–13.
136. Sharifi Milani R, Deville de Periere D, Micallef JP. Relationship between dental occlusion and visual focusing. *Cranio.* 1998;16(2):109–118.
137. Sharifi Milani R, Deville de Periere D, Lapeyre L, Pourreyron L. Relationship between dental occlusion and posture. *Cranio.* 1999;18(2):127–134.
138. Nakata M. Masticatory function and its effects on general health. *Int Dent J.* 1998;48(6):540–548.
139. Garner DP, Dudgeon WD, McDivitt EJ. The effects of mouthpiece use on cortisol levels during an intense bout of resistance exercise. *J Strength Cond Res.* 2011;25(10):2866–2871.
140. Technical Committee PH/3/11. Mouthguards for use in sport and recreation—requirements and test methods. DD 253:2001, British Standards Institute; 2001:4.
141. Kaste LM, Gift HC, Bhat M, Swango PA. Prevalence of incisor trauma in persons 6–50 years of age: United States, 1988–1991. *J Dent Res.* 1996;75 Spec:696–705.
142. Kelly JP, Rosenberg JH. Diagnosis and management of concussion in sports. *Neurology.* 1997;48(3):575–580.
143. Croll TP, Brooks EB, Schut L, Laurent JP. Rapid neurologic assessment and initial management for the patient with traumatic dental injuries. *J Am Dent Assoc.* 1980;100(4):530–534.
144. Lin S, Levin L, Emodi O, Fuss Z, Peled M. Physician and emergency medical technicians' knowledge and experience regarding dental trauma. *Dent Traumatol.* 2006;22(3):124–126.
145. Adair SM, Durr DP. Practical clinical applications of sports dentistry in private practice. *Dent Clin North Am.* 1991;35(4):757–770.
146. Kumamoto DP, Winters JE. Private practice and community activities in sports dentistry. *Dent Clin North Am.* 2000;44(1):209–220.
147. Ranalli DN. Sports dentistry in general practice. *Gen Dent.* 2000;48(2):158–164.
148. Winters JE. Sports dentistry: the profession's role in athletics. *J Am Dent Assoc.* 1996;127(6):810–811.